

Case report

Disseminated fungal infection in a renal transplant recipient involving *Macrophomina phaseolina* and *Scytalidium dimidiatum*: case report and review of taxonomic changes among medically important members of the Botryosphaeriaceae

DARRELL H. S. TAN*, LYNNE SIGLER†, CONNIE F. C. GIBAS† & IGNATIUS W. FONG*

*St Michael's Hospital, Division of Infectious Diseases, Toronto, Ontario, and †University of Alberta Microfungus Collection and Herbarium, Devonian Botanic Garden, Edmonton, Alberta, Canada

We report the first case of human infection with the fungal plant pathogen *Macrophomina phaseolina* in a Sri Lankan-born Canadian man following a renal transplant in India. The patient subsequently succumbed to invasive infection with *Scytalidium dimidiatum*. Molecular sequence analysis confirmed the identification of both fungi and revealed that they are related species within the ascomycete family Botryosphaeriaceae. We review the rationale for the recent reclassification of *S. dimidiatum* as *Neoscytalidium dimidiatum* and of *Natrassia mangiferae* (formerly considered a synanamorph of *S. dimidiatum*) as *Neofusicoccum mangiferae*. This and other recent cases illustrate the potential for plant pathogenic fungi to cause invasive human diseases which are refractory to antifungal therapy.

Keywords *Macrophomina phaseolina*, *Scytalidium dimidiatum*, *Fusicoccum dimidiatum*, *Neoscytalidium dimidiatum*, *Hendersonula toruloidea*, *Natrassia mangiferae*

Introduction

Non-*Aspergillus* species account for an increasing proportion (up to 27%) of invasive mycelial fungal infections in solid organ transplant patients [1]. We describe the first case of human infection by the important plant pathogen, *Macrophomina phaseolina*, in a renal transplant recipient who subsequently died of invasive infection by the related pathogen, *Scytalidium dimidiatum*.

Case report

A 31-year-old man presented to hospital in Toronto, Canada with bloody diarrhea, nausea, vomiting and fever, two months after receiving a living related renal transplant for end-stage renal disease of unknown etiology in Chennai, India. He had emigrated from Sri Lanka to Canada ten years prior to admission. His past medical history was otherwise remarkable only for hypertension, an appendectomy at age 19, and renal stones at age 20. At admission, his medications included immunosuppression with prednisone at 22.5 mg daily in divided doses, 720 mg mycophenolic acid twice daily and cyclosporine A at 150 mg twice daily, as well as telmisartan. He was diagnosed with cytomegalovirus colitis and improved after treatment with valganciclovir.

Received 26 July 2007; Accepted 19 October 2007

Correspondence: I. W. Fong, St Michael's Hospital, Division of Infectious Diseases, 30 Bond Street, Suite 4179, 4th floor Cardinal Carter Wing, Toronto, ON, Canada, M5B 1W8. Tel: +1 416 864 5746; fax: +1 416 864 5310; E-mail: FONGI@smh.toronto.on.ca

Sixteen days after admission, he developed swelling, pain, and purulent discharge involving the left great toe. Swabs of the discharge and an aspirate of the metatarsophalangeal joint yielded very light growth of a filamentous fungus initially thought to represent *Pseudallescheria boydii* based on the grayish colonies. The mycological identification was later revised to *Lasioidiplodia theobromae*, but this identity was also uncertain as the isolate failed to produce typical sporulating structures. DNA sequence data ultimately determined the isolate to be *Macrophomina phaseolina* based on sequence similarity with a reference isolate and a sequence on deposit in GenBank. Treatment was initiated with voriconazole 200 mg twice daily and his symptoms slowly improved.

Ten days later he developed paranoid delusions and hallucinations requiring treatment with risperidone. Computed tomography (CT) without intravenous contrast showed a right posterior temporal hypoattenuating lesion with surrounding edema measuring 3.3 cm. Magnetic resonance imaging (MRI) was performed to better delineate the lesion and revealed a ring enhancing mass measuring 3.0 by 2.5 by 2.5 cm, which was felt to represent either an infarct or abscess (Fig. 1). The patient did not consent to a brain biopsy. Chest X-rays during the same admission showed bilateral thick-walled cavitary lung lesions with ill-defined borders. Bronchoscopy with bronchioalveolar lavage was positive for both

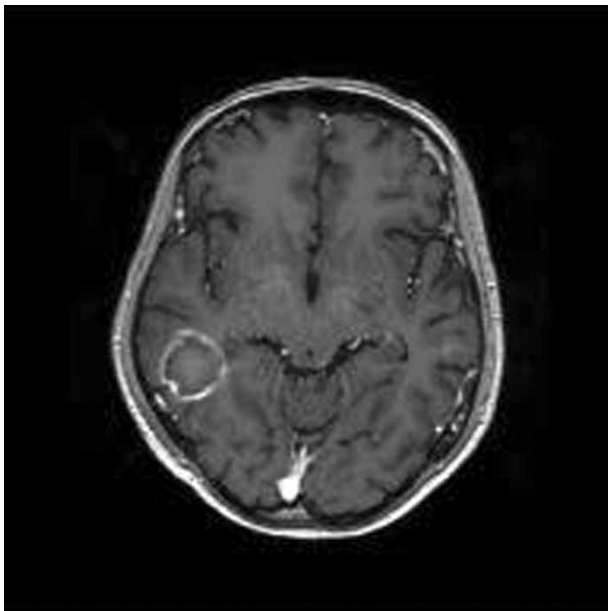


Fig. 1 Gadolinium-enhanced axial T1 magnetic resonance imaging of the head showing a ring-enhancing mass in the right posterior lobe of the renal transplant patient.

Aspergillus species and *Candida glabrata*. Blood cultures were negative and echocardiography was normal. Because of the multiple foci of fungal infection, the decision was made to discontinue all immunosuppressive medications except prednisone, which was continued at a physiologic dose of only 7.5 mg daily. His foot lesion, neurological status, brain lesions and lung cavities all improved on voriconazole therapy, and he was discharged from hospital two months after his initial admission. Voriconazole was ultimately discontinued three months later upon full resolution of his brain lesions on MRI. His renal function stabilized to a creatinine of 200 mmol/l and tacrolimus 3 mg in divided doses was added to his regimen.

Eight months later he was re-admitted to hospital with dysuria, gross hematuria and deteriorating renal function which persisted despite a 7-day course of ciprofloxacin. His renal function improved somewhat with insertion of a nephrouretostomy tube for a partial obstruction of the transplanted kidney. The urine was sterile and pathology for decoy cells was negative. A renal biopsy was performed and revealed patchy inflammatory infiltrate in the interstitium with associated tubulitis, and positive immunostaining for CD4, consistent with acute antibody mediated rejection (Banff grade II). Immediately following the procedure he developed acute hypoxic respiratory failure requiring intubation. Initial blood cultures and bronchoscopy with bronchoalveolar lavage failed to show any evidence of infection so the patient was treated with 3 days of thymoglobulin and a tapering course of high dose corticosteroids in an attempt to salvage the graft. Repeat urine cultures grew *Pseudomonas aeruginosa* which was treated with piperacillin-tazobactam, and itraconazole was added empirically for antifungal coverage.

Though he initially improved, his respiratory and neurological status acutely deteriorated 7 days after intubation. Fever developed, with a maximum temperature of 39.3°C. Two days later he displayed spontaneous decerebrate posturing in the upper extremities, and fixed, asymmetric pupils. Serial CT scans of the brain showed the acute development of obstructive hydrocephalus and an extraventricular drain (EVD) was urgently inserted. Despite these actions the patient deteriorated further, with no demonstrable brainstem function one day later. Family members decided to discontinue life-sustaining therapy. Cerebrospinal fluid (CSF) obtained at the time of EVD insertion grew a filamentous fungus two days after his death, which was subsequently identified as *Scytalidium dimidiatum*.

Mycology

The two patient isolates were referred for identification, approximately 1 year apart, to the University of Alberta Microfungus Collection and Herbarium (UAMH), Edmonton, Alberta, Canada. The isolate from the metatarsophalangeal joint was accessioned as UAMH 10549. When subcultured on potato dextrose agar (Difco Laboratories, Detroit, Mich.) and other media, the isolate produced dark brown sclerotia which were often embedded in the agar. These structures were suspected initially to represent immature pycnidia of *Lasiodiplodia theobromae*, in which sporulation can be recalcitrant. The isolate was grown on a variety of sporulation media (cereal agar, oatmeal salts agar, cornmeal agar, produced in-house) and under different regimes of temperature and light, but it failed to produce pycnidial conidia. DNA sequences from the small subunit (SSU) and internal transcribed spacer (ITS) regions of the nuclear rRNA gene were obtained following procedures for DNA extraction, amplification and sequencing as described previously [2,3]. A BLAST search [4] with the 642 bp product yielded 98% and 95% matches to a complete ITS sequence (AF132795) and a partial SSU-ITS sequence (U97333) of *Macrophomina phaseolina*, the only sequences of this species then available in the GenBank (date 05/2005). All other matches with high E-value scores were sequences from *Botryosphaeria* species or *Fusicoccum* species (anamorphic *Botryosphaeria*). To validate the results, we examined and sequenced an isolate of *M. phaseolina* from the American Type Culture Collection (Manassas, VA), ATCC 62589 (=UAMH 10586). In a pair-wise comparison using Sequencher™ (Gene Codes Corp. Ann Arbor, MI), the ITS sequences from UAMH 10549 (case isolate), ATCC 62589 and AF132795 were 100% identical. A more recent BLAST analysis (date 04/2007) yielded 99% matches to several sequences identified as *M. phaseolina* or *Rhizoctonia bataticola*, now considered to be a synonym of *M. phaseolina* (see taxonomic discussion).

The morphological features of the case isolate and ATCC 62589 of *M. phaseolina* were strongly similar. Colonies on potato dextrose agar reached diameters of 100 mm after 6 days at 30°C and 35°C. They were deeply floccose and dense, initially pale gray, becoming dark gray on the obverse and reverse within 14 days, and produced dark brown to black diffusible pigment (Fig. 2a). Colonies of isolate ATCC 10586 were darker and deeper with strands of mycelium touching the lid of the Petri dish (Fig. 2b). Neither isolate demonstrated growth on medium containing cycloheximide (Mycosel agar, Difco). Hyphae were septate, smooth, subhyaline

to brown, and 1.2 to 8.5 µm wide. Both isolates produced black sclerotia within 7 to 14 days. Sclerotia were discrete, subglobose to irregularly-shaped, measuring 50 µm to 200 µm long, and sometimes coalescing (Fig. 3). Hyphae associated with the sclerotia were sometimes verrucose (Fig. 3b). No pycnidia were produced.

The second isolate, from the CSF specimen, was accessioned as UAMH 10614 and identified as *Scytalidium dimidiatum* based on typical morphological features as described previously [5,6]. Colonies were rapidly growing, deeply floccose with dense ropy aerial mycelium, black on the obverse and reverse. Dark brown to black pigment diffused into the agar. Microscopic examination of slide culture preparations revealed light to dark brown hyphae of varying widths that fragmented to form cylindrical to broadly ellipsoidal arthroconidia. The isolate was grown on sporulation media under different conditions in attempts to induce expression of the coelomycete synanamorph [5], but no pycnidia were obtained.

Sequencing of the CSF isolate was done to confirm that the two patient isolates (UAMH 10549 and 10614) truly represented different species as suggested by their morphological differences. In a pair-wise comparison, the ITS sequences from the two patient isolates were only 84% similar. A BLAST search with the sequence from UAMH 10614 yielded a 99 to 100% match with three sequences identified in the GenBank as *Fusicoccum dimidiatum*, a name recently proposed for *S. dimidiatum* by Farr *et al.* [7] (see taxonomic discussion below), and one sequence of *Scytalidium hyalinum*. These included AY819727 derived from CBS 499.66 (Centraalbureau voor Schimmelcultures, Utrecht, the Netherlands), AY819728 derived from CBS 204.33 (authentic isolate of *Hendersonula toruloides*), AY819726 derived from CBS 251.49 and AY213688 derived from ATCC 38906 (ex-type of *S. hyalinum*). Pair-wise comparison of these four sequences revealed only one bp difference among 460 bp compared.

Antifungal susceptibility testing was performed for each isolate using the CLSI approved method [8]. The MIC's for *M. phaseolina* were amphotericin B 0.06 mg/l, itraconazole 0.015 mg/l, voriconazole 0.015 mg/l, caspofungin 0.015 mg/l, ketoconazole 0.03 mg/l, fluconazole 0.12 mg/l, and 5-fluorocytosine 4 mg/l. The *Macrophomina* isolate did not grow very well even in 72 h. The MIC's for *S. dimidiatum* were amphotericin B 0.25 mg/l, itraconazole 1 mg/l, voriconazole 0.06 mg/l, caspofungin 0.5 mg/l, ketoconazole 2 mg/l, fluconazole 8 mg/l, and 5-fluorocytosine 4 mg/l.

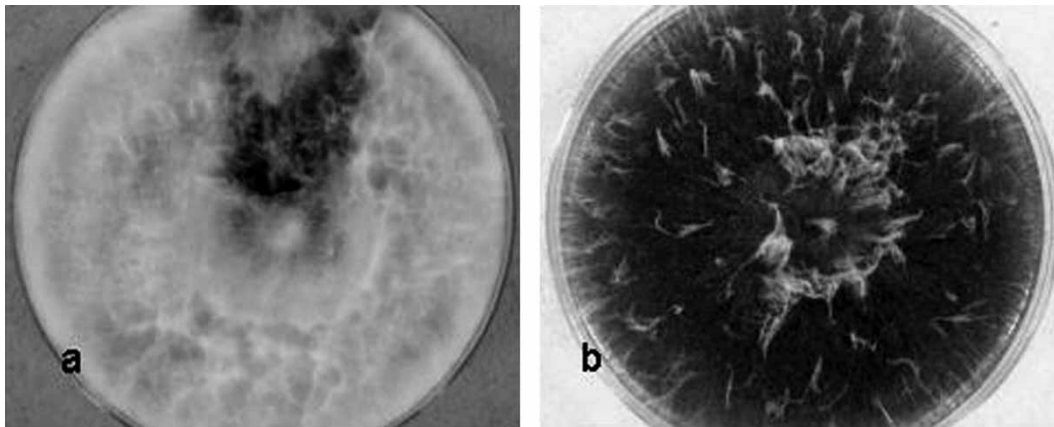


Fig. 2 Colonies of *Macrophomina phaseolina* grown on potato dextrose agar after 6 days at 30°C. Colonies of the case isolate UAMH 10549 (a) are paler than those of ATCC 62589 (UAMH 10586) (b).

Discussion

Several aspects of this patient's case warrant discussion. First, this represents the first report of human infection by the important plant pathogen, *M. phaseolina*. Subcutaneous infection on the tail of a cat has been attributed to *M. phaseolina* [9], but the authors' description of slow growth at 37°C and their illustration of the conidia suggest that a different fungal species was probably the etiologic agent. *M. phaseolina* has been recorded as infecting 500 plant species worldwide, causing charcoal root rot of economically important crops such as bean, sorghum, cotton, chickpea, soybean and corn [10]. The organism is soil borne and has a worldwide distribution, including the Americas, Asia, Africa, and parts of Europe, suggesting that our patient may have acquired the infection through environmental exposures either in Canada or in Sri Lanka. Various strategies to control this fungus have been studied in the agricultural setting. These

include co-cultivation with strains of *Pseudomonas aeruginosa* [11,12], ethanol extracts of the brown alga *Spatoglossum asperum* [13], and conventional antibiotics, such as tetracycline, ampicillin, griseofulvin and agrimycin, which have been shown to inhibit growth of *M. phaseolina in vitro* by 73.9%, 50.9%, 40.7%, and 13.0%, respectively, at concentrations of 1000 µg/ml [14]. Antifungal susceptibility data suggest that *M. phaseolina* is susceptible to several antifungal agents and our patient's infection responded to treatment with voriconazole alone.

The finding of a second fungal plant pathogen in the same patient is another unusual aspect of this case. *Scytalidium dimidiatum* produces arthroconidia in culture, and some isolates also produce pycnidia under appropriate growth conditions. The coelomycetous synanamorph has been given the separate name *Natrassia mangiferae*, previously known as *Hendersomula toruloidea* (see taxonomic discussion below). This

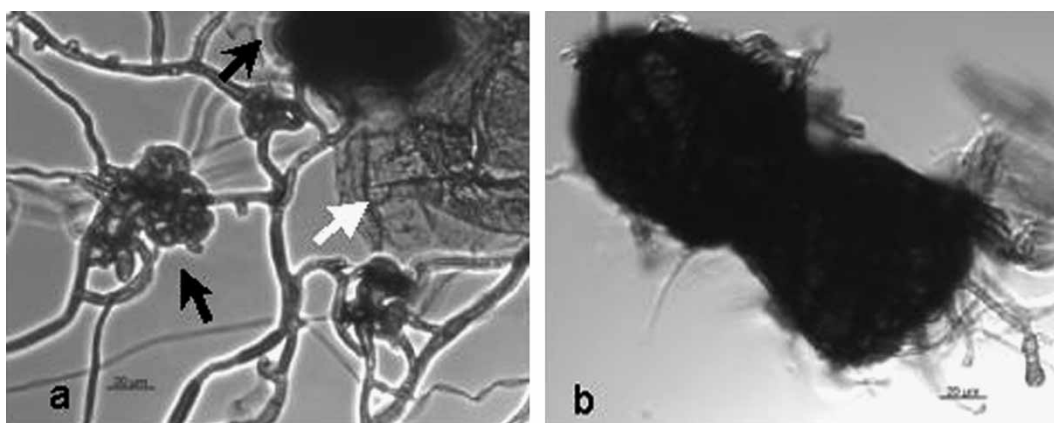


Fig. 3 Sclerotia of *Macrophomina phaseolina* are shown. A slide culture mount (a) shows developing sclerotia (black arrows) and diffusible pigment (white arrow), and a tease mount (b) shows an irregularly-shaped mature sclerotium.

species also is an important plant pathogen causing significant pathology in fruit trees, other woody plants, and economically important crops in tropical and subtropical areas worldwide. In recent years, *S. dimidiatum* has been well established as an agent of dermatomycosis, affecting the nails, toe webs, soles and occasionally palms, of individuals who have emigrated or traveled from regions such as South America, Southeast Asia, India, the Caribbean and Africa. Infections are often clinically indistinguishable from dermatophyte infections, and mixed infections with dermatophytes also have been reported [15–18]. *S. dimidiatum* is distinguished from dermatophytes by its characteristic sinuous, irregular hyphal appearance in direct microscopy of cutaneous specimens, fast growing black colonies and sensitivity to cycloheximide. Infection is presumed to occur through contact with contaminated plant material or soil, and possibly through direct contact with infected nail or skin. Virulence factors involved in the pathogenesis of *Scytalidium* dermatomycosis may include the elaboration of a keratinase which facilitates invasion of skin [19], and a fungal pigment which mediates resistance to phagocyte-produced oxygen radicals [15].

The acquisition of the *S. dimidiatum* infection in our patient most likely occurred in Sri Lanka, his country of origin, or in India, where he obtained his renal transplant. Dissemination from toenail lesions was ruled out because the patient had no history or evidence of onychomycosis. A high prevalence of *S. dimidiatum* infection occurs in areas where the fungus is known to be endemic, including parts of West and Central Africa, the Caribbean, and Asia [reviewed in 6,15]. In Thailand, this fungus is now the leading cause of fungal foot disease [20,21]. The prevalence of infection in North America is low [22–24]. A few cases acquired in North America have been reported, including nail and scalp infections [25–27], subcutaneous infection in a diabetic man who lived in Arizona where the fungus was found to be endemic [6,28], a post-traumatic hand infection in an immunocompetent man from Texas [29] and an invasive sinusitis case discussed below in a woman from Utah [30].

Relatively few cases of deep infection caused by *S. dimidiatum*, or its hyaline counterpart, *S. hyalinum*, have been reported. Sigler *et al.* [6] reviewed therapy and outcome in 11 cases of subcutaneous and invasive infection in which underlying risk factors included diabetes mellitus, chronic obstructive lung disease, corticosteroid therapy, hypertension, trauma, and immunosuppression. Eight additional reports concern invasive disease in immunocompromised hosts and

infections following trauma in otherwise healthy hosts. An Australian patient with advanced AIDS (CD4 count $<10 \times 10^6$ /liter) developed infection caused by two different fungi, similarly to our case [31]. *S. dimidiatum* was the cause of indurated skin lesions on the feet and inguinal regions, with inguinal lymphadenitis and lymphangitis. The concomitant sinusitis was attributed to *Lecytophora hoffmannii*, but later examination by Sigler revealed the isolate to represent a *Phaeoacremonium* species. Invasive sinusitis occurred in a neutropenic lung transplant recipient more than two years after transplantation [30]. This patient had a long history of chronic rhinosinusitis, but no record of exposure to *S. dimidiatum* through travel within or outside the United States. Disseminated infection involving diffuse skin lesions, pulmonary infiltrates and vertebral involvement occurred in a renal transplant patient [32]. The first skin lesion in this case was localized on the hallux. Underlying systemic lupus erythematosus and therapy with high dose corticosteroid and cyclophosphamide were risk factors in an Iranian patient who succumbed to a brain abscess [33]. Another Iranian patient with underlying diabetes mellitus, heart failure and cirrhosis died of invasive orbital infection following trauma with a piece of wood [34]. Two cases of eye infection occurred following corneal laser surgery in an immunocompetent patient [35] and trauma in a patient with underlying diabetes, heart failure and cirrhosis [36]. A thorn puncture predisposed a Pakistani field worker to mycetoma [37].

Treatment is difficult, with poor responses to treatment despite MICs that are within achievable concentration ranges in serum and tissue [6,15]. Ketoconazole generally has been ineffective [6,29], but some reports describe limited success [36,37]. Combinations of ketoconazole and natamycin [35] and itraconazole and amphotericin B [34] were ineffective in treating eye infections. Amphotericin B [6] alone or in combination with voriconazole [30,32] has induced clinical and mycological remission in a few cases of deep infection, but amphotericin alone was ineffective in treating cerebral infection [33]. Given the acute deterioration of our patient, and the lack of definitive evidence of fungal infection until after his death, it is difficult to assess the adequacy of his brief exposure to itraconazole and voriconazole.

The separation in time of over one year between our patient's two episodes of invasive fungal infection is a third unusual finding. Renal transplant recipients are at greatest risk of fungal infection during the first two months after transplantation [38], although the risk of opportunistic infection never completely disappears. Our patient's initial presentation occurred within 2

months of transplantation, but the episode of fungal infection which culminated in his death occurred more than one year later. The long delay between the two events could reflect two independent exposures, but given the usual epidemiology of *S. dimidiatum* infections described above, it is more likely that both infections were acquired in Sri Lanka or India. Active infection of the allograft, which was obtained in Chennai, is unlikely, as such infections typically manifest during the first month post-transplantation. Instead, a remote exposure of the patient, presumably by a pulmonary route, to a common plant or soil reservoir appears more likely, but it is surprising that the *S. dimidiatum* infection did not occur earlier in his clinical course. It is very likely that the initial brain lesion was an abscess caused by *S. dimidiatum*, which showed improvement on voriconazole, but not complete eradication.

Definitive identification of both isolates from our patient was performed by sequence analysis due to absence of sporulation in the first isolate, and differences in sporulation pattern with the second isolate. Our findings constitute a final novel aspect of this case as they shed light on the taxonomy of these clinically uncommon organisms. Our phylogenetic analysis (data not shown) revealed that *M. phaseolina* and *S. dimidiatum* are related anamorphic fungi within the ascomycete family Botryosphaeriaceae, a result somewhat surprising since the taxonomic affinity of *M. phaseolina* was not then known. The Botryosphaeriaceae has been subject of several recent taxonomic revisions based on sequence data. In the most recent one, Crous *et al.* [39] used analysis of 28S rDNA sequences to resolve lineages within the family and to propose new genera and species. Their data showed that *M. phaseolina* isolates form a distinct clade (clade 3) within the family; that *Tiarospora phaseoli* and *Rhizoctonia bataticola* are synonyms of *M. phaseolina* and that there are no connections to known *Botryosphaeria* teleomorphs. Unusual morphological features of *M. phaseolina* include the black sclerotia (Fig. 3 and [10]), and the presence of two mucoid appendages on the apical ends of immature, hyaline pycnidial conidia. Mature brown conidia lack appendages and have a truncate base (illustrated in [39]). Both isolates examined by us produced sclerotia but failed to produce the pycnidial conidia under any growth condition.

The production of both arthroconidial and pycnidial (*Natrassia*) synanamorphs has led to taxonomic and nomenclatural controversy in *Scytalidium dimidiatum* [reviewed in 6]. In the phylogenetic tree of Crous *et al.* [39], isolates producing arthroconidia typical of *S. dimidiatum* were placed in a distinct clade (clade 4)

separate from the clade (clade 6) including isolates obtained from mango which lacked this synanamorph, and for which the species *Natrassia mangiferae* had been described (originally under the name *Dothiorella mangiferae*). The *N. mangiferae* isolates grouped with species formerly treated in the genus *Fusicoccum*. Crous *et al.* proposed the new genus *Neoscytalidium*, with type species *Neoscytalidium dimidiatum*, for *S. dimidiatum* and they listed its coelomycete synanamorph, *Hendersonula toruloidea*, as a synonym. A new genus was required because the type species of *Scytalidium*, *S. lignicola*, grouped within the Leotiomycetes (see also [40]) and outside the *Botryosphaeria* clade (Dothidiomycetes). These data clearly support arguments made previously that *S. lignicola* and *S. dimidiatum* are distinct species [6]. Crous *et al.* also rejected as incorrect, the decision by Farr *et al.* [7] to place *Scytalidium* into synonymy with *Fusicoccum* and to rename *S. dimidiatum* as *Fusicoccum dimidiatum*. Another new genus, *Neofusicoccum*, was described to accommodate *Neofusicoccum parvum* (= *Fusicoccum parvum*), *Neofusicoccum mangiferae* (= *Natrassia mangiferae*) and several other species having *Botryosphaeria*-like teleomorphs [39].

Our case demonstrates the ongoing risk of opportunistic fungal infections posed to recipients of solid organ transplants on immunosuppressive therapy. Our patient represents the first known human infection with the plant fungus *M. phaseolina*, and he subsequently succumbed to a second invasive fungal infection with *S. dimidiatum*. Sequence analyses demonstrate that both fungi are related species within the family Botryosphaeriaceae and that *Neoscytalidium dimidiatum* is the new and correct name for clinical isolates demonstrating typical arthroconidia and formerly known as *Scytalidium dimidiatum*, *Fusicoccum dimidiatum*, or *Hendersonula toruloidea*. *Neofusicoccum* (*Natrassia*) *mangiferae* represents a different species which occurs on mango and lacks arthroconidia and this name should no longer be used as an alternative name for clinical isolates of *Neoscytalidium dimidiatum*. Three members of the Botryosphaeriaceae, including *M. phaseolina*, *N. dimidiatum* and *Lasiodiplodia theobromae*, may cause dermatomycosis or deep infection, and it seems likely that other members of this cosmopolitan family of plant pathogenic fungi will be shown to cause human infection.

Nucleotide sequence accession numbers

Sequences were deposited into the GenBank database as EF507502 (SSU) and EF570501 (ITS) for UAMH

10549, EF570500 for UAMH 10586 and EF570499 for UAMH 10614.

Acknowledgements

L. Sigler thanks the Natural Sciences and Engineering Research Council of Canada for financial support. The authors thank C. Sand, National Reference Centre in Mycology, University of Alberta Hospitals, Edmonton, Alberta, for results of antifungal susceptibility. Potential conflicts of interest: All authors: no conflicts.

References

- Husain S, Alexander BD, Munoz P, et al. Opportunistic mycelial fungal infections in organ transplant recipients: emerging importance of non-*Aspergillus* mycelial fungi. *Clin Infect Dis* 2003; **37**: 221–229.
- Gibas CF, Sigler L, Summerbell RC, Currah RS. Phylogeny of the genus *Arachnomycetes* and its anamorphs and the establishment of *Arachnomycetales*, a new eurotiomycete order in the *Ascomycota*. *Stud Mycol* [serial on the Internet – cited 20 February 2007]. 2002; **47**: 123–130. Available from: <http://www.cbs.knaw.nl/publications/>
- Sigler L, Gibas CFC. Utility of a cultural method for identification of the ericoid mycobiont *Oidiodendron maius* confirmed by ITS sequence analysis. *Stud Mycol* [serial on the Internet – cited 20 February 2007]. 2005; **53**: 63–74. Available from: <http://www.cbs.knaw.nl/publications/>
- Altschul SF, Madden TL, Schäffer AA, et al. Gapped BLAST and PSI-BLAST: a new generation of protein database search programs. *Nucleic Acids Res* 1997; **25**: 3389–3402.
- Sigler L, Carmichael JW. Taxonomy of *Malbranchea* and some other Hyphomycetes with arthroconidia. *Mycotaxon* 1976; **4**: 349–488.
- Sigler L, Summerbell RC, Poole L, et al. Invasive *Natrassia mangiferae* infections: case report, literature review, and therapeutic and taxonomic appraisal. *J Clin Microbiol* 1997; **35**: 433–440.
- Farr DF, Elliott M, Rossman AY, Edmonds RL. *Fusicoccum arbuti* sp. nov. causing cankers on pacific madrone in western North America with notes on *Fusicoccum dimidiatum*, the correct name for *Scytalidium dimidiatum* and *Natrassia mangiferae*. *Mycologia* 2005; **97**: 730–741.
- Clinical and Laboratory Standards Institute. Reference method for broth dilution antifungal susceptibility testing of filamentous fungi. Approved standard. M38-A. Wayne, PA: National Committee for Clinical Laboratory Standards, 2002.
- Hasegawa T, Yoshida Y, Kosuge J, et al. Subcutaneous granuloma associated with *Macrophomina* species infection in a cat. *Vet Rec* 2005; **156**: 23–24.
- Holliday P, Punithalingam E. *Macrophomina phaseolina*. CMI Descriptions of Pathogenic Fungi and Bacteria. No. 275. 1988.
- Bhatia S, Bhatia S, Dubey RC, Maheshwari DK. Antagonistic effect of fluorescent pseudomonads against *Macrophomina phaseolina* that causes charcoal rot of groundnut. *Indian J Exp Biol* 2003; **41**: 1442–1446.
- Shaukat SS, Siddiqui IA. The influence of mineral and carbon sources on biological control of charcoal rot fungus, *Macrophomina phaseolina* by fluorescent pseudomonads in tomato. *Lett Appl Microbiol* 2003; **36**: 392–398.
- Ara J, Sultana V, Qasim R, Ehteshamul-Haque S, Ahmad VU. Biological activity of *Spatoglossum asperum*: a brown alga. *Phytother Res* 2005; **19**: 618–623.
- Dubey RC. Effect of some antibiotics on *Macrophomina phaseolina*, a charcoal rot fungus of soybean. *Hindustan Antibiot Bull* 1989; **31**: 38–39.
- Hay RJ. *Scytalidium* infections. *Curr Opin Infect Dis* 2002; **15**: 99–100.
- Gupta AK, Elewski BE. Nondermatophyte causes of onychomycosis and superficial mycoses. *Curr Top Med Mycol* 1996; **7**: 87–97.
- Hay RJ, Moore MK. Clinical features of superficial fungal infections caused by *Hendersonula toruloidea* and *Scytalidium hyalinum*. *Br J Dermatol* 1984; **110**: 677–683.
- Lacroix C, Kac G, Dubertret L, et al. Scytalidiosis in Paris, France. *J Am Acad Dermatol* 2003; **48**: 852–856.
- Oycka CA, Gugnani HC. Keratin degradation by *Scytalidium species* and *Fusarium solani*. *Mycoses* 1998; **41**: 73–76.
- Ungpakorn R. Mycoses in Thailand: current concerns. *Nippon Ishinkin Gakkai Zasshi* 2005; **46**: 81–86.
- Ungpakorn R, Lohaprathan S, Reangchainam S. Prevalence of foot diseases in outpatients attending the Institute of Dermatology, Bangkok, Thailand. *Clin Exp Dermatol* 2004; **29**: 87–90.
- Ghannoum MA, Hajjeh RA, Scher R, et al. A large-scale North American study of fungal isolates from nails: the frequency of onychomycosis, fungal distribution, and antifungal susceptibility patterns. *J Am Acad Dermatol* 2000; **43**: 641–648.
- Gupta AK, Jain HC, Lynde CW, et al. Prevalence and epidemiology of onychomycosis in patients visiting physicians' offices: A multicenter Canadian survey of 15,000 patients. *J Am Acad Dermatol* 2000; **43**: 244–248.
- Summerbell RC, Kane J, Krajden S. Onychomycosis, tinea pedis and tinea manuum caused by non-dermatophytic filamentous fungi. *Mycoses* 1989; **32**: 609–619.
- Elewski BE, Greer DL. *Hendersonula toruloidea* and *Scytalidium hyalinum*. *Arch Dermatol* 1991; **127**: 1041–1044.
- Frankel DH, Rippon JW. *Hendersonula toruloidea* infection in man. *Mycopathologia* 1989; **105**: 175–186.
- Kane J, Poretta M, Krajden S, Goldhar J, Diena BB. An autochthonous phaeohyphomycotic nail infection in Canada caused by *Hendersonula toruloidea*. *Mycoses* 1990; **33**: 37–40.
- Matheron ME, Sigler L. First report of Eucalyptus dieback caused by *Natrassia mangiferae* in North America. *Plant Dis* 1994; **78**: 432.
- Levi ME, Smith JW. Posttraumatic infection due to *Scytalidium dimidiatum*. *Clin Infect Dis* 1994; **18**: 127–128.
- Dunn JJ, Wolfe MJ, Trachtenberg J, et al. Invasive fungal sinusitis caused by *Scytalidium dimidiatum* in a lung transplant recipient. *J Clin Microbiol* 2003; **41**: 5817–5819.
- Marriott DJE, Wong KH, Aznar E, et al. *Scytalidium dimidiatum* and *Lecythophora hoffmannii*: unusual causes of fungal infections in a patient with AIDS. *J Clin Microbiol* 1997; **35**: 2949–2952.
- Willinger B, Kopetzky G, Harm F, et al. Disseminated infection with *Natrassia mangiferae* in an immunosuppressed patient. *J Clin Microbiol* 2004; **42**: 478–480.
- Geramishoar M, Zomorodian K, Zaini F, et al. First case of cerebral phaeohyphomycosis caused by *Natrassia mangiferae* in Iran. *Jpn J Infect Dis* 2004; **57**: 285–286.
- Sadeghi Tari A, Mardani M, Rahnavardi M, et al. Post-traumatic fatal *Natrassia mangiferae* orbital infection. *Int Ophthalmol* 2005; **26**: 247–250.

- 35 Jabbarvand M, Hashemian MR, Abedinifar Z, Amini A. *Nattractasia mangiferae* keratitis after laser in situ keratomileusis. *J Cataract Refract Surg* 2004; **30**: 268–272.
- 36 Gumbo T, Mkanganwi N, Robertson VJ, Masvaire P. Case report. *Nattractasia mangiferae* endophthalmitis. *Mycoses* 2002; **45**: 118–119.
- 37 Aamir S, Aman S, Haroon T. Mycetoma caused by *Scytalidium dimidiatum*. *Br J Dermatol* 2003; **148**: 174–176.
- 38 Rubin RH, Wolfson JS, Cosimi AB, Tolkoff-Rubin NE. Infection in the renal transplant patient. *Am J Med* 1981; **70**: 405–411.
- 39 Crous PW, Slippers B, Wingfield MJ, et al. Phylogenetic lineages in the Botryosphaeriaceae. *Stud Mycol* [serial on the Internet – cited 1 December 2006]. 2006; **55**: 235–253. Available from: <http://www.cbs.knaw.nl/publications/>
- 40 Hambleton S, Sigler L. *Meliniomyces*, a new anamorph genus for root-associated fungi with phylogenetic affinities to *Rhizoscyphus ericae* (\equiv *Hymenoscyphus ericae*), *Leotiomyces*. *Stud Mycol* [serial on the Internet – cited 20 February 2007]. 2005; **53**: 1–27. Available from: <http://www.cbs.knaw.nl/publications/>