

# Toenail infection by *Cladophialophora boppii*

J. BRASCH\*, S. DRESSEL\*, K. MÜLLER-WENING\*, R. HÜGEL\*, D. VON BREMEN\* & G.S. DE HOOG†

\*Department of Dermatology, University Hospitals of Schleswig-Holstein, Campus Kiel, Kiel, Germany, and †CBS Fungal Biodiversity Centre, Utrecht, The Netherlands

*Cladophialophora boppii* is a black yeast-like fungus that up to now has been only rarely described as a cause of human infection and whose role as a pathogen was not established despite its repeated isolation and genetic identification in these reports. Here we report the first case of a verified toenail infection caused by this fungus in a woman without any systemic disease or evidence of immunodeficiency. Identical dark molds were isolated from the same toenail at three points of time. Species identification was performed by scrutinizing the isolates morphologic, physiologic and genetic characteristics which resulted in their identification as *Cladophialophora boppii*. Oral treatment with terbinafin plus topical ciclopiroxolamine was effective.

**Keywords** onychomycosis, black fungi, phenotype, physiology, ITS sequence, antifungal agents

## Introduction

Dermatophytes are the most common fungi that cause nail infections worldwide, but under favorable conditions, many molds can also invade nails [1]. The spectrum of fungi capable of inducing onychomycoses may be larger than commonly assumed [2] because in daily routine operations of clinical laboratories non-dermatophyte fungi recovered from nails are easily dismissed as contaminants. However, if meticulous and repeated investigations are done, even rare fungal species can sometimes be proven to be true pathogens [3]. Among the rare etiologic agents consistently causing superficial mycoses are melanized molds belonging to the order *Chaetothyriales* (black yeasts and relatives [4]). These fungi are oligotrophic, i.e., able to thrive under nutritionally adverse conditions [5] and hence are frequently encountered in human bathing facilities. Lian and de Hoog [6] suggested that infections might take place through minor wounds and skin breaks. Here we report the first case of a nail infection caused by the black yeast-like fungus *Cladophialophora boppii* in an

immunocompetent woman, which is also the first case of an infection by this fungus that was repeatedly confirmed over a period of time.

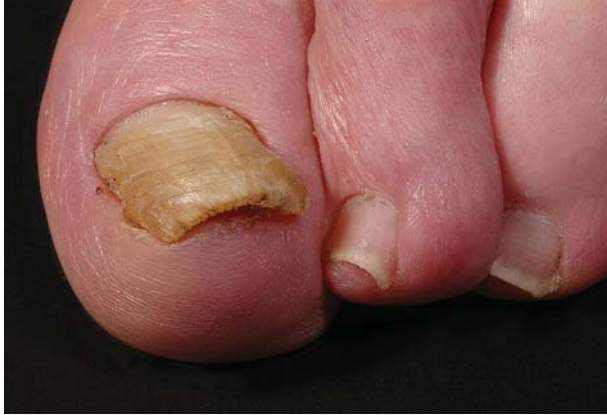## Case report

A 70-year-old woman was referred to the dermatological department of the university hospital in Kiel, Germany, for treatment of recalcitrant ulcers on her lower legs that had developed as a side-effect of venous insufficiency. Apart from this problem her general health was good. By the time of admission to the hospital, alterations of both of her big toenails were noted as a secondary finding. The patient herself had not been aware of her nail changes which were strongly suggestive of onychomycosis.

Clinical examination revealed a brownish discoloration and thickening of approximately the distal 80% of her left and right big toenail, and under the distal ends of the nail plates crumbly debris was visible (Fig. 1). Samples were collected from such subungual debris under her left first nail for mycological investigation in February 2009. The potassium hydroxide mount was positive, revealing elongated pigmented and septate fungal elements. Sabouraud's glucose agar plates with antibiotics (bioMérieux, Marcy-l'Etoile, France) both with cycloheximide (400 mg l<sup>-1</sup>, AppliChem, Darmstadt, Germany) and without cycloheximide were inoculated with nail material and incubated at 26°C. Identical colonies of dark

Received 1 July 2010; Received in final revised form 13 August 2010; Accepted 15 August 2010

Correspondence: Jochen Brasch, Department of Dermatology, University Hospitals of Schleswig-Holstein, Campus Kiel, Schittenhelmstraße 7, D-24105 Kiel, Germany. Tel: +49 431 597 1507; fax: +49 431 597 1611; E-mail: jbrasch@dermatology.uni-kiel.de

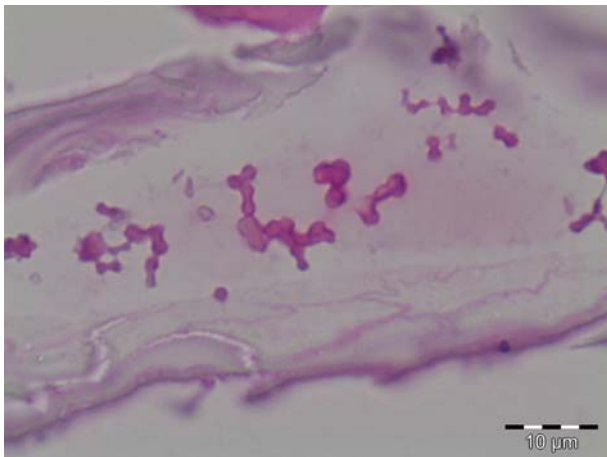


**Fig. 1** Distal subungual onychomycosis of the left big toenail.

molds developed on all plates. Based on their micro-morphology and physiology (see below) the molds were classified as a *Cladophialophora* species.

*Cladophialophora* species are not known to cause onychomycosis. Therefore, an antimycotic treatment was postponed and instead new samples were collected from both toenails at a later visit of the patient in May 2009. In addition, a clipping from the distal left big toenail was used to prepare histological slides. The same melanized fungus noted on her initial visit was recovered in culture and the histological specimen showed rather thick fungal elements in PAS stains (Fig. 2).

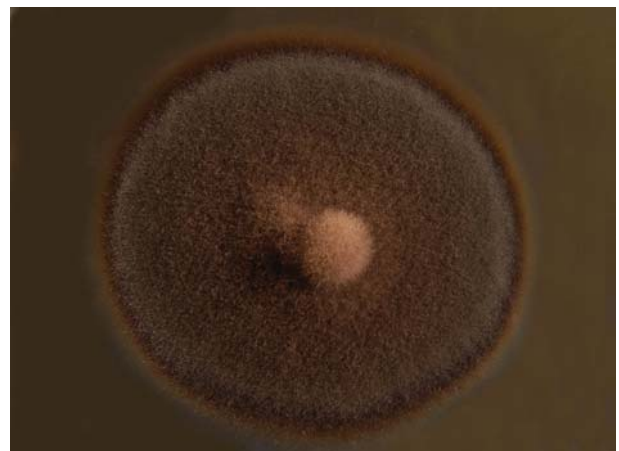Before treatment was started, new nail material was collected once more in October 2009, and the same fungus was isolated. We also tested this nail sample for the presence of dermatophytes through the use of a PCR with DNA extracted from the nail material and a pan-derm primer suitable for all dermatophytes [7]. No dermatophyte was detected by this method.



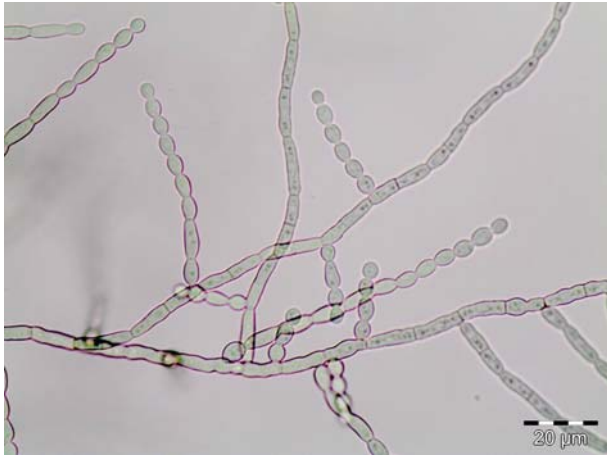
**Fig. 2** Thick fungal elements in histological specimen of the nail; PAS stain.

Subsequently therapy was applied involving oral administration of terbinafine 250 mg/day for 6 weeks and topical application of ciclopiroxolamine. Under this regimen a steady replacement of the discoloured nail parts occurred and continued until normal nails and negative cultures were finally recorded after 3 months.

Three strains collected in February, May and October were sent to the Centraalbureau voor Schimmelcultures (CBS) KNAW Fungal Biodiversity Centre in Utrecht, The Netherlands, for definite identification. The ITS sequence of one of these morphologically identical strains (CBS accession no. CBS 127448; GenBank HQ114280) was 100% identical to the ex-type strain of *Cladophialophora boppii* (Borelli) de Hoog *et al.*, CBS 126.86. In addition, the morphology and the physiology of all the three strains collected from our patient were compared with meticulous care in the mycological laboratory of the Department of Dermatology in Kiel. The findings were identical for all isolates and indicated they were olivaceous-black melanized hyphomycetes with rather slow growth at 26°C on Sabouraud's agars without and with 0.1 % cycloheximide (Fig. 3), but no growth at 37°C. Microcultures showed dark and rather thick- and smooth-walled septate hyphae, with branches that acropetally developed into elongating chains of smooth-walled, subspherical conidia (Fig. 4). The urease test was positive, but assimilation of *meso*-erythritol was negative and growth was inhibited by 10% NaCl supplemented to Sabouraud's glucose agar. However, inoculation on pure horn flakes that had been collected from human plantar skin, autoclaved and put into Petri dishes with distilled water, resulted in a slow growth of nearly black colonies (Fig. 5) at 26°C. The antifungal susceptibility testing done by E-tests® (VIVA-Diagnostika, Cologne, Germany) for fluconazole and itraconazole showed no zones of inhibition.



**Fig. 3** Melanized thallus of *Cladophialophora boppii* on Sabouraud's agar.

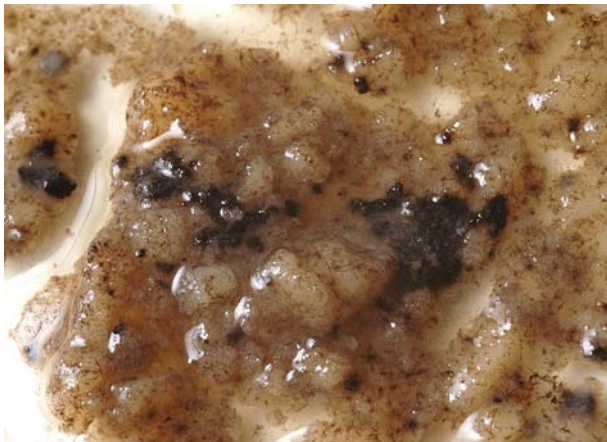


**Fig. 4** Thick- and smooth-walled septate hyphae with chains of smooth-walled conidia.

## Discussion

*Cladophialophora boppii* is a black yeast-like fungus that is not commonly encountered in human infections. It was first isolated by C. Bopp in 1983 (CBS 126.86) and described by Borelli under the name *Taeniolella boppii* as an agent which according to these authors had caused chromomycosis in a Brazilian woman [8,9]. Later it was reclassified as *Cladophialophora boppii* by de Hoog *et al.* [10] based on molecular phylogenetic studies.

The CBS collection contains several strains of *C. boppii* that have been confirmed by sequencing. CBS 110029 was isolated from skin scales of human patients in The Netherlands, CBS 110028 originated from human hair in Germany, and five strains were isolated in the course of a study of cutaneous infections in Denmark [Saunte DM *et al.*, Unit of Bacteriology, Mycology and



**Fig. 5** Dark colonies of *Cladophialophora boppii* growing on pure flakes of human stratum corneum.

Parasitology, Statens Serum Institut, Copenhagen, Denmark; unpublished data]. The species thus is probably associated with superficial infections of human skin. A literature search in Medline revealed only one single published case of a pulmonary infection in a transplant recipient ascribed to *C. boppii* [11]. However, the method by which *C. boppii* was identified was not specified in this report, sequences were not available, and the inability of the isolate to grow at 37°C makes it unlikely that this species was identified correctly.

In the Danish study involving 20,746 symptomatic, immunocompetent individuals, 2.2% of all culture positive samples strongly suggested that *Cladophialophora boppii* and related black fungi are underdiagnosed [Saunte DM *et al.*, Unit of Bacteriology, Mycology and Parasitology, Statens Serum Institut, Copenhagen, Denmark; unpublished data]. Nearly all strains were derived from humans as sole agents of infection. In our case we are convinced that *C. boppii* was in fact the etiologic agent of nail discoloration. The fungus was isolated in triplicate within a time span of 8 months from the same nail, while no dermatophyte was found in culture or by genetic analysis. We could also demonstrate that *C. boppii* grows on human stratum corneum *in vitro*. Therefore it can be assumed that, in principal, the fungus is able to colonize nails as well.

Phylogenetically *Cladophialophora boppii* is on the one hand related to *Cladophialophora chaetospora*, which can be found on decaying plant matter, and on the other hand to agents of chromoblastomycosis. This disease resulting from traumatic inoculation occurs in the tropics and is mostly due to *Cladophialophora carrionii* or to some *Fonsecaea* species [12,13]. Mild cutaneous infections and infections of nails possibly occur without prior injury, or may result from minor skin injuries. Recently it was also shown that *C. boppii* can grow on media with anion surfactants and that it is able to degrade soap [14]. Lian and de Hoog [6] found *C. boppii* (CBS 124175) colonizing bathing facilities. These properties may also convey a reduced susceptibility to detergents used for skin cleaning and thus make the fungus more resistant to such measures. The authors hypothesized that these fungi gained entrance into macerated skin by minor skin injuries. Distal subungual onychomycosis as seen in our patient usually starts with an inoculation of infectious fungal material under the free edge of a nail. On the feet this can occur during walking barefoot on soil containing fungal propagules. However, our patient could give no information about the history of her nail infection because she had not taken any notice of it. She had never visited a tropical country.

Little is known about physiologic features that might relate to pathogenic properties of *C. boppii*. One relevant

point, however, is the fact that growth of *C. boppii* is inhibited or very restricted at 37°C [10]. This inability to adapt to the human central temperature certainly excludes systemic infection. However, we demonstrated that growth on keratin at 26°C is possible, which principally allows infection of superficial skin.

Terbinafin was chosen for treatment of our patient. This is a well established antimycotic drug for onychomycoses caused by dermatophytes and various molds and also shows *in vitro*-activity against several *Cladophialophora* species [15]. Furthermore our *in vitro*-tests did not reveal that our isolate was susceptible to fluconazole or itraconazole. Terbinafin was effective in our patient but its *in vivo* efficacy against other strains of *C. boppii* needs to be confirmed by future experience.

Our observation once again highlights that the full spectrum of fungi capable of causing onychomycosis still remains to be explored. Even in otherwise healthy individuals and in clinically unremarkable cases a surprising diversity of species may be involved. Therefore, if an unlikely fungus is grown from nail material it should not prematurely be dismissed as a contaminant. Instead, further accurate diagnostic investigations may be quite rewarding.

### Acknowledgements

The authors wish to thank Vera Beck-Jendroscheck and Karin Voss for their skilful technical assistance.

**Declaration of interest:** The authors report no conflicts of interest. The authors are responsible for the content and writing of the paper.

This paper was first published online on Early Online on 14 October 2010.

### References

- 1 Hay R. Literature review. Onychomycosis. *J Eur Acad Dermatol Venereol* 2005; **1**: (Suppl. 19): 1–7.
- 2 Iorizzo M, Piraccini BM, Tosti A. New fungal nail infections. *Curr Opin Infect Dis* 2007; **20**: 142–145.
- 3 Brasch J, Varga J, Jensen JM, Egberts E, Tintelnot K. Nail infection by *Aspergillus ochraceopetaliformis*. *Med Mycol* 2009; **47**: 658–662.
- 4 Li DM, de Hoog GS, Saunte DM, van den Ende AH, Chen XR. *Coniosporium epidermidis* sp. nov., a new species from human skin. *Stud Mycol* 2008; **61**: 131–136.
- 5 Satow MM, Attili-Angelis D, de Hoog GS, Angelis DF, Vicente VA. Selective factors involved in oil flotation isolation of black yeasts from the environment. *Stud Mycol* 2008; **61**: 157–163.
- 6 Lian X, de Hoog GS. Indoor wet cells harbour melanized agents of cutaneous infection. *Med Mycol* 2010; **48**: 622–628.
- 7 Brillowska-Dabrowska A, Saunte DM, Arendrup MC. Five-hour diagnosis of dermatophyte nail infections with specific detection of *Trichophyton rubrum*. *J Clin Microbiol* 2007; **45**: 1200–1204.
- 8 Bopp C, Vettoratto, Borelli D. Chromoblastomycosis caused by a new species: *Taeniolella boppii*. *Med Cutan Ibero Lat Am* 1983; **11**: 221–226.
- 9 Borelli D. *Taeniolella boppii*, a new species, causative agent of chromomycosis. *Med Cutan Ibero Lat Am* 1983; **11**: 227–232.
- 10 de Hoog GS, Guého E, Masclaux F, et al. Nutritional physiology and taxonomy of human-pathogenic *Cladosporium-Xylohypha* species. *J Med Vet Mycol* 1995; **33**: 339–347.
- 11 Lastoria C, Cascina A, Bini F, et al. Pulmonary *Cladophialophora boppii* infection in a lung transplant recipient: case report and literature review. *J Heart Lung Transplant* 2009; **28**: 635–637.
- 12 López Martínez R, Méndez Tovar LJ. Chromoblastomycosis. *Clin Dermatol* 2007; **25**: 188–194.
- 13 Ameen M. Chromoblastomycosis: clinical presentation and management. *Clin Exp Dermatol* 2009; **34**: 849–854.
- 14 Hamada N, Abe N. Fungal growth on anion surfactant medium. *Biocontrol Sci* 2009; **14**: 177–180.
- 15 Vitale RG, Perez-Blanco M, de Hoog GS. *In vitro* activity of antifungal drugs against *Cladophialophora* species associated with human chromoblastomycosis. *Med Mycol* 2009; **47**: 35–40.