

A tendency to use thick catgut at operation is due to an unfounded fear that fine stitches may be insufficiently strong to hold the wound edges in apposition. Great force is not normally necessary to keep a wound closed and even if considerable strain is expected, as in retching or coughing after laparotomy, it is more likely that the sutures would cut out of the tissues than that the stitches themselves would break.

The shearing strain of tissues, which is analogous to their resistance to the cutting out of stitches, is not so high as appears to be generally believed, varying from less than 1 lb. in soft tissue, as for instance bowel, to no more than 2½ lb. in rectus muscle sheath. The minimum standard breaking strain for No. 2/0 catgut, even when knotted, is 3 lb. This bears out the experiments of various workers who advocate the use of finer catgut sutures than those commonly used, with No. 0 for fascia as the thickest recommended, down to No. 3/0 or No. 4/0 for muscle, peritoneum and subcutaneous tissue (Howes, 1929, 1941).

Suspected infection in a wound need not be a reason for using thick catgut; besides the addition of 'thick catgut reaction' to the bacterial disturbance, it is by no means certain that a moderate infection speeds up the absorption of catgut excessively. In a summary of a large number of abdominal wound disruptions, it was found that the cases in which infection was present disrupted considerably *later* than the clean cases.

Furthermore, with the considerable improve-

ments in the manufacture of surgical catgut over recent years resulting in greater tensile strength, there is no justification on this score for using the thicker sizes.

### Conclusion

To summarize the points covered in this general survey of catgut as a suture material:—

1. The fundamental advantage of catgut is its absorbability.
2. It has excellent tensile strength.
3. Sterility, as taken from the sealed tubes, is assured.
4. A hardened or 'chromed,' catgut is preferable to the 'plain' variety.
5. The finest possible sizes should be used in preference to thicker sizes.

In conclusion, the following quotation from Mikulicz is offered with respect and sincerity:—

*'Je reconnais le bon chirurgien, non pas à la façon dont il coupe, mais à la façon dont il sait recoudre.'*

### BIBLIOGRAPHY

- FANDRE, A. (1944), 'Le Catgut,' Masson et Cie, Paris.  
 WILLIAMS, F. E. (1936), 'Alcohol and Sporing Organisms,' *Med. Jour. Australia*.  
 HOLDER, E. J. (1939), 'Surgical Sutures and Ligatures,' E. & S. Livingstone, Edinburgh.  
 HOLDER, E. J. (1946), 'Desirable Factors in Surgical Sutures,' Wm. Blackwood & Sons, Ltd., Edinburgh.  
 JENKINS, H. P., *et al.* (1942), *Arch. Surg.*, **44**, 881, 984.  
 JENKINS, H. P., *et al.* (1942), *Ibid.*, **45**, 74.  
 JENKINS, H. P., *et al.* (1942), *Ibid.*, **45**, 323.  
 HOWES, E. L., and HARVEY, S. C. (1929), *New Eng. J. Med.*, **200**, 1285.  
 HOWES, E. L. (1941), *Surg. Gyn. and Obst.*, **73**, 319.

## HIND-QUARTER AMPUTATION

By L. P. LE QUESNE, M.A., F.R.C.S.

*Second Assistant, Surgical Professorial Unit, Middlesex Hospital*

Hind-quarter amputation was first performed in 1891 by Billroth (1902), but it was not until 1895 that a successful result was obtained by Girard (1895). Since that time the operation has been performed by many surgeons with increasing success. Pack and Ehrlich (1946) report that 132 cases are recorded in surgical literature over the last 50 years. Sir Gordon Gordon-Taylor, in 1946, reported a personal series of 21 cases, and since that time has performed a further 11 such operations; it is largely as a result of his work that this formidable ablation has been established in this country as a standard procedure in the surgical management of malignant disease.

In most cases the operation is performed for primary malignant tumours of the bones or connective tissues of the pelvis, or for similar tumours in the upper third of the thigh which have extended too far proximally to allow of disarticulation through the hip-joint; typical of the tumours necessitating this procedure are those illustrated in Figs. 1 and 2. On occasion the operation has been performed for extensive tuberculous or chronic inflammatory disease of the hip and pelvic bones. By virtue of their less sinister pathological potentialities, the best results are obtained in cases where the tumour is essentially only of local malignancy, such as infiltrating chondromas of the

ilium and giant neurofibromas of the sacral plexus; but brilliant results have been obtained in the treatment of grossly malignant tumours, and the purely palliative relief given in many cases is of considerable value. Whilst there can be no doubt that the operation is one of the most formidable in surgery, it is also certain that in properly selected and handled cases it can give results more than commensurate with the risks and anxieties incurred.

### Pre-Operative Preparation

Any significant degree of anaemia is, of course, corrected before operation and the general state of the patient's health is carefully assessed. Some 24 hours before operation courses of penicillin and a suitable sulphonamide are started as a prophylactic measure. Immediately before operation an intravenous drip should be set up and a gum-elastic urethral catheter tied in; to avoid disturbing the patient these two procedures are carried out after anaesthesia has been induced. Owing to the likely need for rapid massive transfusion it is advisable to set up two intravenous drips. In most cases these are both inserted in the forearm of the side not involved in the operation, in which position they are readily accessible and can be controlled by one person without impeding the operating team.

Once the patient has been put in position on the table, with drips and catheter in place, two final preparations remain to be done, the application of an Esmarch bandage as an exsanguinating tourniquet from toes to mid-thigh, and the stitching in place of a veil of oiled silk to cover over and isolate the anus. This veil is stitched close to the anus to avoid encroaching on the operative field.

### Anaesthesia and Control of Transfusion

The usual pre-operative injection of omnopon and scopolamine is given one hour before operation. Many forms of anaesthetic would serve satisfactorily for this operation, but the following technique has given excellent results in several cases and seems to fulfil most requirements. Anaesthesia is induced with pentothal, following which a nasal endotracheal tube is passed, after preliminary spraying of the larynx with cocaine; anaesthesia is then maintained with nitrous oxide and ether administered through the tube. After placing the patient on the operating table a unilateral spinal block is given, using 10 ml. of 1/1,500 light nupercaine. With this technique all painful stimuli are interrupted and only a light plane of general anaesthesia need be maintained.

Once the operation has begun a blood transfusion should be started at such a rate that most of the first pint has been administered at the com-

pletion of the anterior dissection. During the posterior dissection, especially if sacro-iliac disarticulation is performed, shock is likely to be more marked, and is often exacerbated by haemorrhage from the gluteal region. Accordingly during this time rapid transfusion is required, and it is now that two drips may prove their value (Figs. 3 and 4). Usually 3 or 4 pints of blood are required during and immediately after the operation, and a further 1 pint administered some 6 to 7 hours post-operatively is often valuable. In some cases however considerably greater quantities of blood may be required, and 8 to 10 pints should be ready cross-grouped before operation.

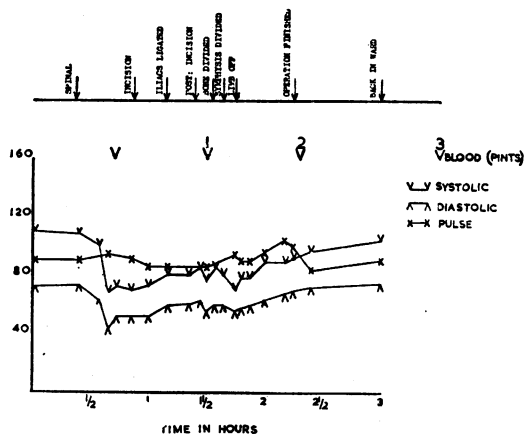


FIG. 3.—Graph showing blood pressure and pulse during an uncomplicated hind-quarter amputation. Compare with Fig. 4.

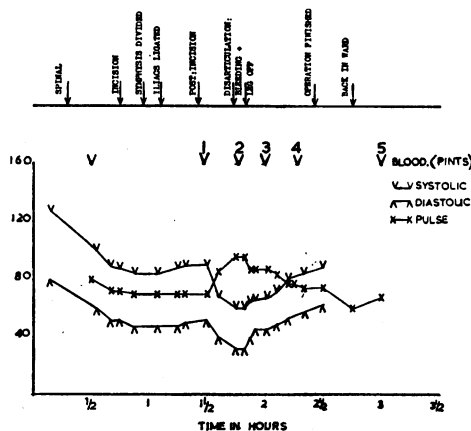


FIG. 4.—Similar graph to Fig. 3, showing the serious degree of shock associated with sacro-iliac disarticulation. Note the improvement consequent upon rapid, massive transfusion. (Figs. 3 and 4 are reproduced by kind permission of Dr. Brian Sellick, who gave the anaesthetic in these two cases.)

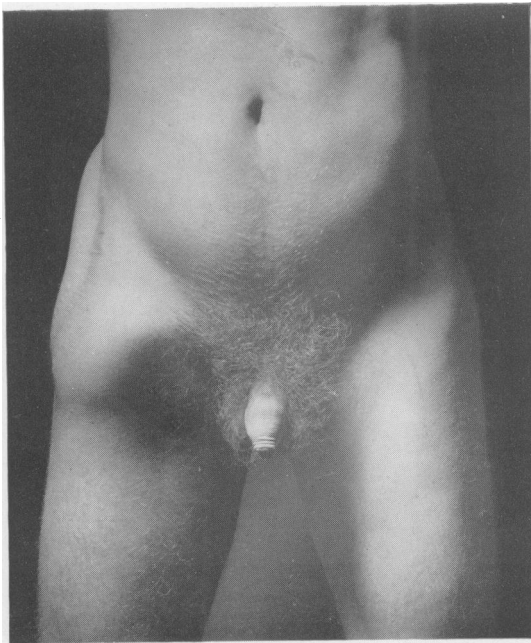

FIG. 1.—A typical case requiring hind-quarter amputation. This man had an infiltrating chondrosarcoma of the ilium, extending so far back that sacro-iliac disarticulation was necessary. The scar of an attempted previous local excision is visible.

### Position on the Table

The patient is placed lying on his sound side but tilted slightly towards the surgeon who stands behind the patient. One sandbag is placed in the small of the back and another behind the sound thigh. The upper arm is fixed on an arm rest as for nephrectomy, whilst the lower is held out on a board. The leg to be amputated is held by an assistant; the other two assistants stand one opposite the surgeon and the other by his side.

### Operation

The incision employed is a modification of that designed by Girard (Fig. 5). Starting at the posterior superior iliac spine it runs forwards  $\frac{1}{2}$  to 1 in. above the iliac crest, and continues down above the inguinal ligament until just short of the pubic spine, where it is carried down across the adductor origins. Posteriorly the incision runs from the posterior superior spine to the ischial tuberosity and thence follows the gluteal fold to join the anterior portion. Only the anterior portion of the incision is made at first; in the region of the iliac crest this incision is immediately deepened through all layers of the abdominal wall to enter the extraperitoneal space over a distance of 3 to 4 in. A hand is then inserted, and the peritoneum swept off the lateral

wall of the pelvis as far forwards and downwards as possible (Fig. 6). This most important step enables the surgeon to explore the internal extent of the tumour and to gauge its invasion of the peritoneum at an early stage of the operation. If the tumour appears irremovable, the operation can be abandoned before important vessels have been ligated.

The division of the flat muscles of the abdominal wall is then continued down to the pubis, the cord being carefully swept medially and upwards with the peritoneum. This line of division may pass  $\frac{1}{2}$  in. above Poupart's ligament, running through the muscular internal ring and across the posterior wall of the inguinal canal, or the inguinal ligament may be detached from bone at both ends and left attached to the abdominal musculature. In either case the deep epigastric artery must be secured and divided (Fig. 7). The bladder is then separated from the back of the pubis and from the rectus muscle, which is divided at its attachment to the pubis (Fig. 8).

The peritoneum is now stripped widely from the lateral pelvic wall, and the ureter, which remains with the peritoneum, is carefully identified and preserved. The external iliac artery and vein are dissected out and divided between heavy silk ligatures, followed by ligation in continuity of the internal iliac vein and the posterior division of the internal iliac artery (Fig. 9). If isolation of this latter vessel is difficult, it is permissible to ligate the internal iliac artery itself, but preservation of its anterior division is to be preferred. After division of these vessels the obturator nerve is identified and divided. The anterior part of the dissection is then completed by division of the psoas muscle, the upper part of the origin of the iliacus, the femoral nerve and the lateral cutaneous nerve of the thigh. The inner aspect of the sacro-sciatic notch is now visible (Fig. 10).

For the posterior dissection the patient is rolled gently away from the surgeon and, after the incision has been made, the flap is dissected up medially and posteriorly. The gluteus maximus is preferably included in the flap, but in some cases the extent of the tumour may not permit this (Fig. 11). A little dissection will now expose the posterior aspect of the sacro-sciatic notch, and after division of the origin of the glutei, a Gigli saw can be passed through the notch and the wing of the ilium divided outwards and backwards. The saw is best inserted by passing the points of a Moynihan's forceps through the notch from within the pelvis and then withdrawing the wire in their teeth. After division of the ilium, the bone should be retracted laterally and the pubic symphysis divided; this can often be done with a knife but a chisel may be necessary, and in any

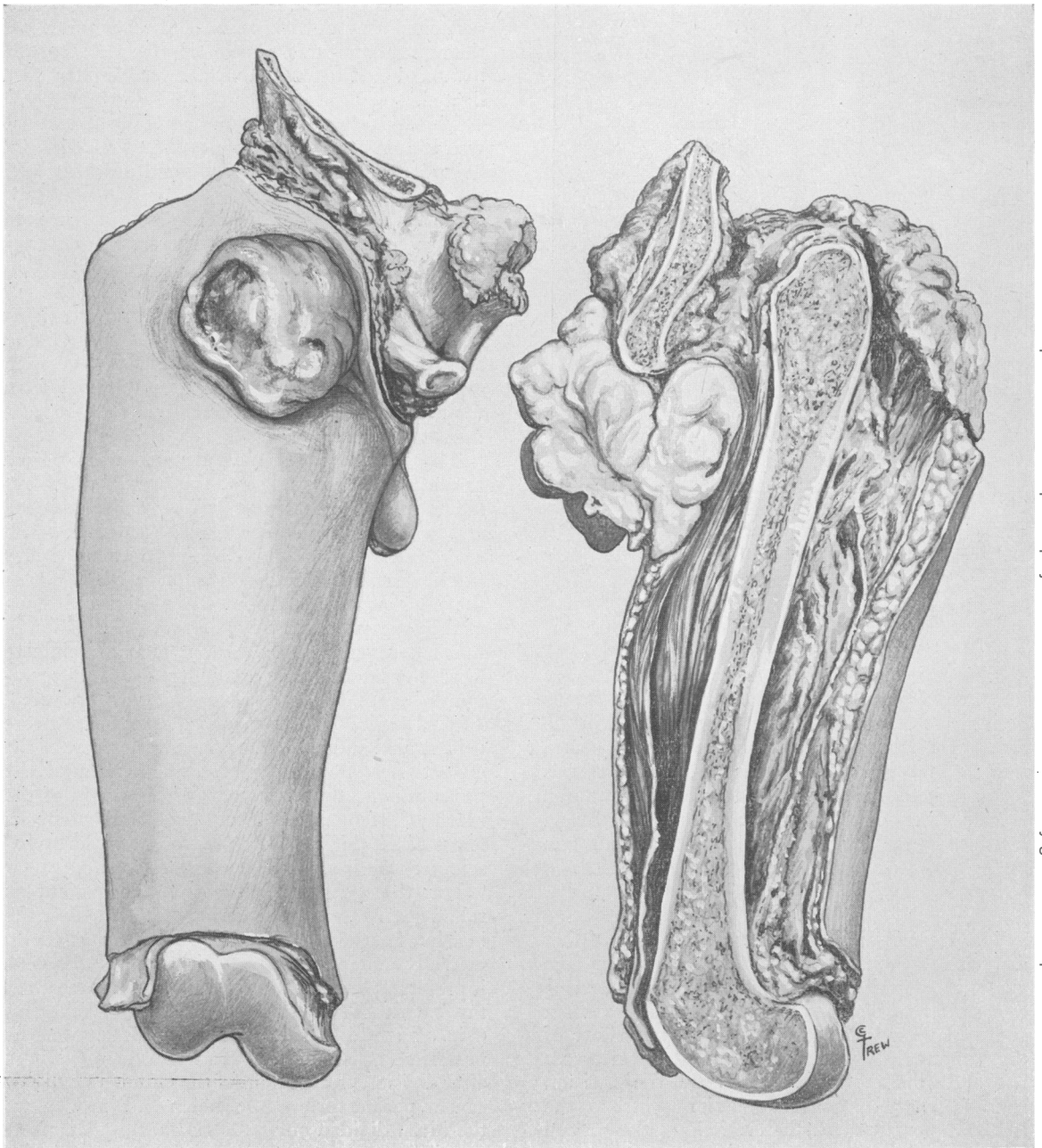


FIG. 2.—Two views of a specimen removed by hind-quarter amputation. This man had a reticulum-cell sarcoma of the inguinal lymph glands, which had recurred after heavy irradiation. The tumour was infiltrating the ilium and ulcerating through the skin.

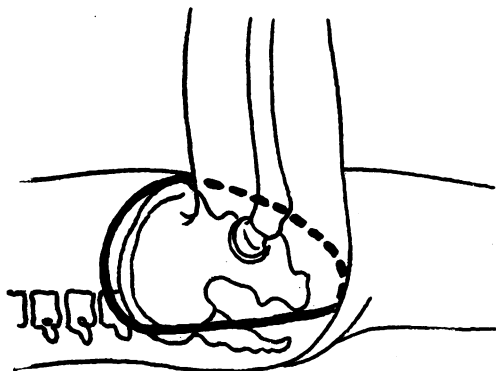


FIG. 5a.—Diagram illustrating the incision used for hind-quarter amputation. In certain cases modifications may be required to secure adequate flaps.

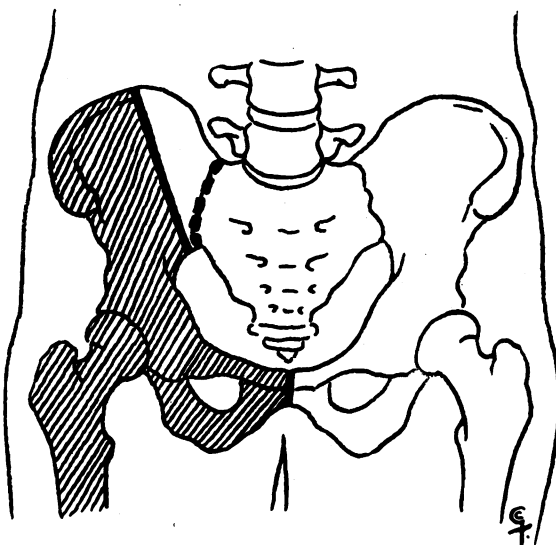


FIG. 5b.—Diagram to show the lines of bone section. The shaded area shows the amount of bone normally excised, though on occasion sacro-iliac disarticulation may be required, as shown by the dotted line.

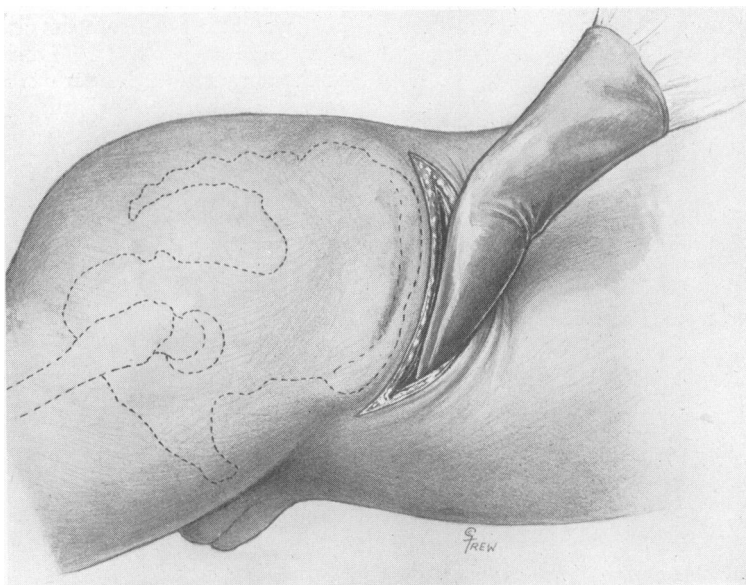


FIG. 6.—The incision parallel to the iliac crest has been deepened through the muscles, and a hand is inserted to explore the inward, pelvic extent of the tumour.

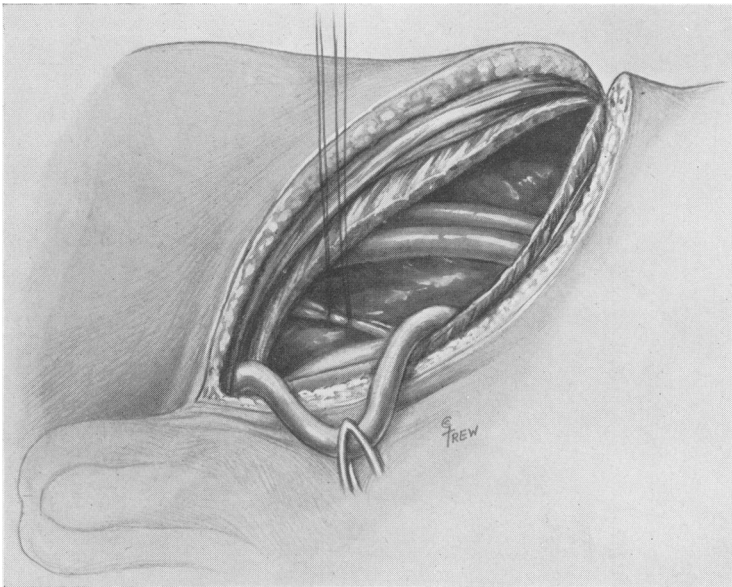


FIG. 7.—The ligation of the inferior epigastric vessels. The spermatic cord has been mobilized and retracted well medially.

case the division is made easier by lateral retraction of the pelvis.

Completion of these two basic sections now allows the half pelvis to be drawn and rotated laterally, and in this position the crus penis should be detached from the pubic ramus, the knife being kept close to the bone throughout (Fig. 12). Turning now to the inner aspect of the pubis, the thick, anterior, pubo-rectalis portion of the levator ani should be identified; both surfaces of the entire levator can then be cleared

and divided from before backwards (Fig. 13), care being taken to retract the rectum medially. It now remains only to turn the pelvis forwards again and divide the piri-formis muscle, the sciatic nerve, the sacro-tuberous and sacro-spinous ligaments and the limb will be free, the nerve and muscle being cut as they leave the pelvis, and the two ligaments close to the tuberosity and spine respectively. During this last stage of the amputation the various smaller nerves and vessels leaving the pelvis through the sacro-sciatic

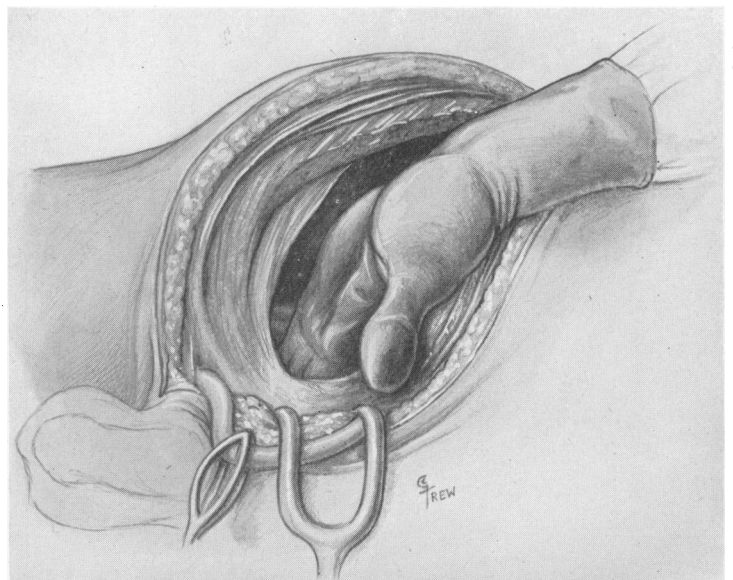


FIG. 8.—With a hand inserted to retract and shield the bladder and peritoneum, the rectus muscle is detached from the pubis.

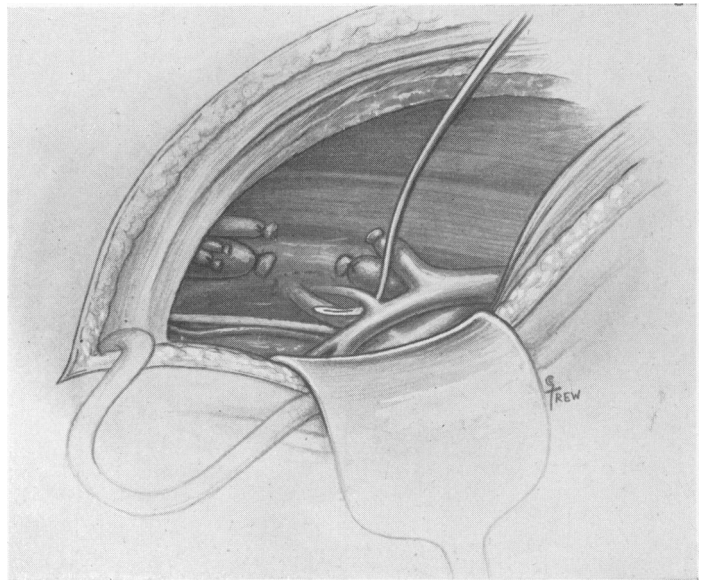


FIG. 9.—Ligation of the posterior division of the internal iliac artery. The external iliac vessels have already been divided between ligatures. The obturator nerve can be seen lying just below the apex of the sacro - sciatic notch, which has been dotted in to demonstrate its position in relation to the vessels.

notch are divided, but time is not wasted in identifying them.

Following removal of the limb careful attention is given to haemostasis, and after dusting with penicillin powder the wound is closed. This closure can usually be done in two layers, first muscle then skin ; a large corrugated drain, passed deep to the muscles, is brought out posteriorly. The dressings should be firmly strapped in position with long lengths of broad elastoplast.

**Modifications**

The procedure described is not applicable to all cases, because in some the tumour extends so far proximally that division through the sacro-sciatic notch is not practicable. In such cases there remains the alternative procedure of sacro-iliac disarticulation (Fig. 5b). There can be no doubt that this materially increases the severity of the operation. It is unnecessary for all cases but is invaluable in some. The disarticulation is performed most easily from the front, after careful

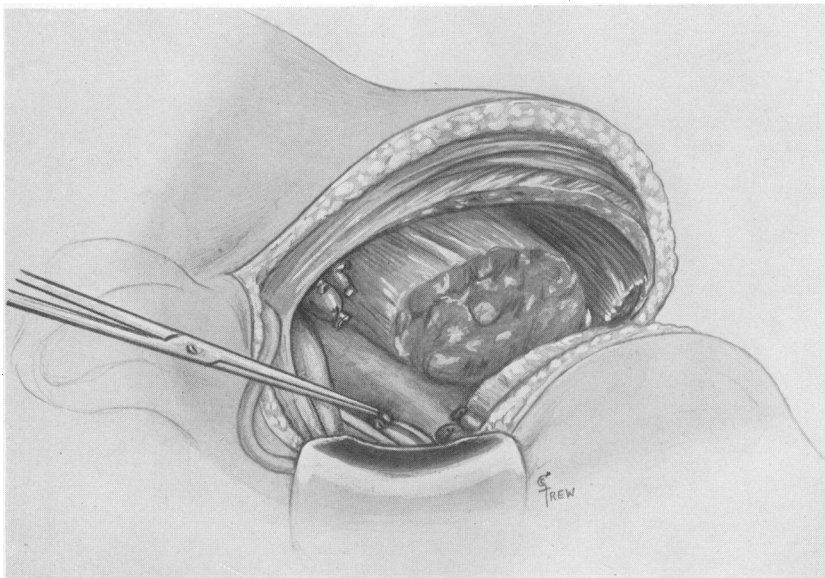


FIG. 10.—The anterior dissection has been completed by section of the psoas and iliacus muscles, between which two structures can be seen the divided femoral nerve. Forceps have been inserted into the sacro-sciatic notch, at the site of bone section.

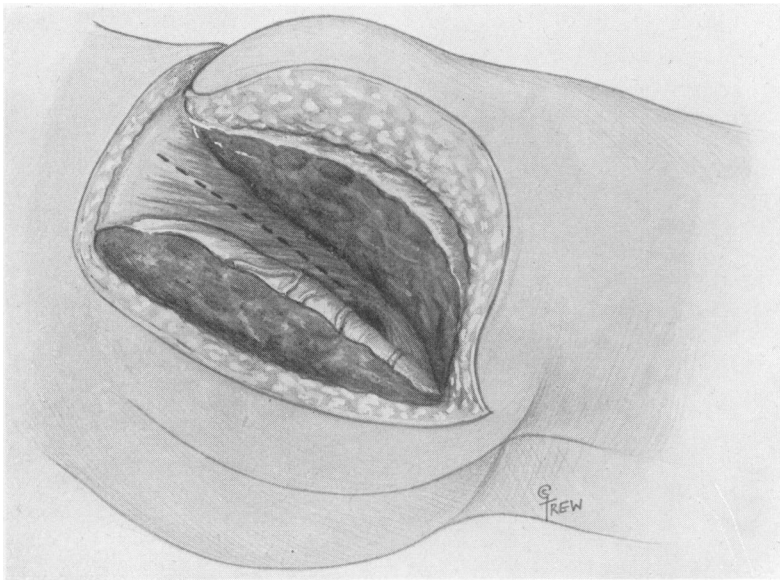


FIG. 11.—The posterior incision has been deepened through the gluteus maximus, to expose the posterior aspect of the sacro-sciatic notch. The dotted line indicates the line of division of the ilium.

retraction of the iliac vessels from the surface of the joint. When the joint space has been identified a chisel is used to separate the two bones, and in using this instrument it is essential to remember that the joint lies obliquely, and that the chisel must be directed backwards and inwards towards the midline. Apart from this one major variant, there are many minor alterations in incision and procedure which may be necessary in certain cases but do not essentially alter the operation.

#### Post-Operative Care

On return to the ward the patient is placed on a water bed, with the foot raised on blocks and a

sandbag against the sound hip. The blocks are removed and the drip regulated according to the state of the patient, usually both being dispensed with by the morning after operation. The catheter should be connected to a Duke's or tidal drainage apparatus, and can be removed on the third to fourth post-operative day when normal micturition usually returns.

The first dressing, preferably under light anaesthesia, is done on the third or fourth day when the drain is removed; thereafter the dressing is changed as necessary. The skin sutures should not be removed hastily, as the flaps take time to unite firmly and some sloughing of

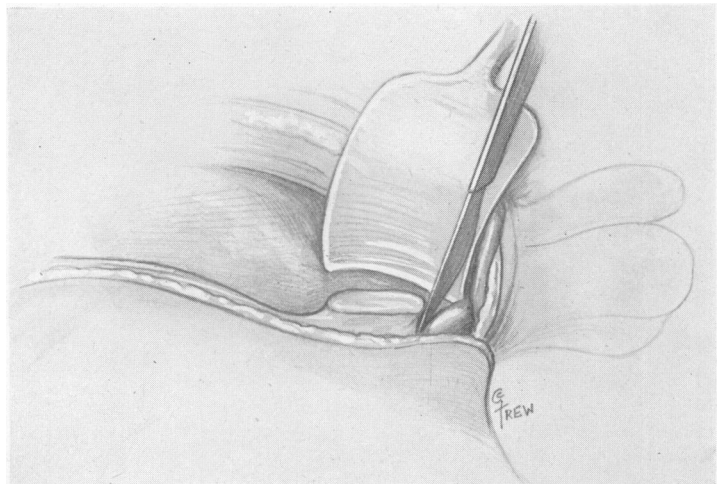


FIG. 12.—A diagram to show the crus penis being cut off the pubic ramus, after both bone sections have been made and the half-pelvis retracted laterally and backwards.



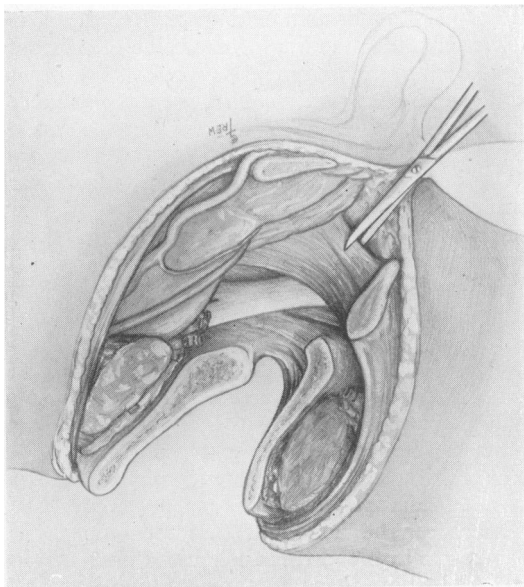


FIG. 13.—The levator ani is divided from before backwards, its anterior, pubo-rectalis portion being thick and muscular. During this procedure the rectum, bladder, prostate, and peritoneum must be protected from injury. The sciatic nerve can be clearly seen running across the face of the piriformis muscle: the ureter, vas and cord are also shown, in contact with the peritoneum.

the posterior flap may occur. Removal should not be begun before ten days and some stitches may well be left for 15 days.

Whilst the patient is confined to bed careful attention is paid to the pressure points, the patient being rolled to either side for attention to his back; nor should the remaining heel be overlooked. Usually the patient gets up on the seventh post-operative day, and as strength returns can be taught to use crutches.

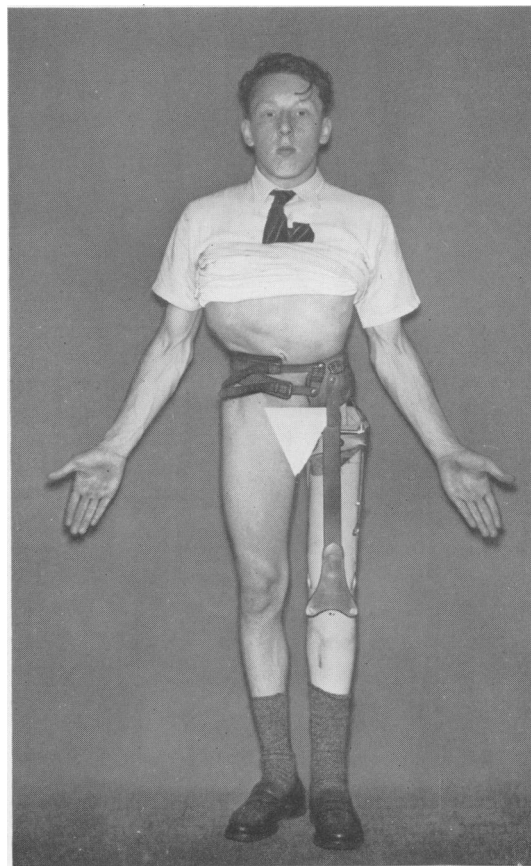
During the first two to three weeks after operation a close watch is kept on the haemoglobin level, and it may well be necessary to give a further transfusion some ten days after the operation. During this period the patient often becomes generally depressed and exhausted as a result of the strain of the operation and a full realization of the extent of the ablation, and apart from physical measures encouragement and sympathy from surgeon and sisters are of paramount importance.

### Discussion


Fortunately the circumstances requiring performance of a hind-quarter amputation are not common. Equally fortunately, coincident with the operation being put on a sound anatomical and surgical basis, modern developments have largely

diminished the two great problems associated with it in the past—the immediate risk to the patient owing to the magnitude of the operation and the subsequent disability following so extensive an ablation.

In 1935 Gordon-Taylor and Wiles (1935) found that the mortality rate in 55 cases collected from the literature was 56.4 per cent., but by 1946 Gordon-Taylor and Patey (1946) were able to report 80 cases from various sources with a recovery rate of 82 per cent., and on a personal series of 21 cases with 71 per cent. recovery. Similarly Pack and Ehrlich (1946) report that 'during the past quarter of a century the operative mortality has been gradually lowered from 50 per cent. to about 15 per cent.,' and go on to record a personal series of six cases involving sacro-iliac disarticula-



FIGS. 14 and 15.—V.P., 2½ years after left hind-quarter amputation; he is wearing the special prosthesis referred to in the text. Note the compensatory scoliosis, which frequently develops. (These two photographs are reproduced by kind permission of the Director of Medical Services, Roehampton Hospital, and of Mr. Ivor Lewis, F.R.C.S.)



tion without a death. Sir Gordon Gordon-Taylor's personal series now amounts to 32 cases, with eight deaths; during the past few months, of the four hind-quarter amputations performed on this unit only one has given rise to undue anxiety, and he ultimately died on the 16th post-operative day.

Involving as it does section of considerable muscle masses, division of bone, often heavy retraction and, on occasions, severe haemorrhage, the operation is inevitably associated with a considerable degree of shock, and to undertake it without adequate preparations for extensive and rapid transfusion is to court disaster. However, unlike many patients with extensive growths presenting themselves for operation, patients requiring hind-quarter amputation are usually in fair general condition and do not exhibit gross systemic and nutritional disorders. Furthermore, the problem presented is the straightforward acute one of combating shock and haemorrhage, unaccompanied by the immediate and remote complications of radical operations involving extensive

resections of abdominal or thoracic viscera. With the better understanding of the value of adequate transfusion in the treatment of shock, this problem has been at least partly solved with a consequent substantial reduction in the mortality (Figs. 3 and 4).

Until recently, after this operation patients were compelled for the rest of their lives to rely on crutches for getting about, and in spite of the assurance and agility that many developed the disability was severe. Within recent years, however, there has been developed at Roehampton a prosthesis which enables these cases to walk well. The leg is secured by abdominal straps and no shoulder band is required (Figs. 14, 15, 16). Though patients wearing this limb have a pronounced limp, its development has been of great value in improving both their appearance and their self-reliance. A stick is usually necessary.

There can be no doubt that the modern developments in blood transfusion and limb-making discussed above have materially diminished the hazards and drawbacks to the hind-quarter amputation. It nevertheless remains a formidable procedure, and its successful performance depends upon team work. Throughout the whole of the pre-operative treatment, operation and post-operative period, close co-operation between the surgeon, his assistants and the nursing staff is essential. If severe haemorrhage occurs during the operation it may well need all the efforts of surgeon, anaesthetist and transfusion officer to see the patient safely through, whilst during the post-operative phase it is only by unremitting attention to detail that success can be attained.

It is impossible to give adequate expression of my thanks to Sir Gordon Gordon-Taylor for his advice, encouragement and constant assistance in the preparation of this article, and further for the access he has allowed me to the records and pictures of his cases. My thanks are also due to Mrs. C. G. Trew and the staff of the Photographic Department of the Middlesex Hospital for their skill and care in the preparation of the illustrations, as also to Mr. R. S. Monro and others who assisted me in the necessary dissections.

#### BIBLIOGRAPHY

- BILLROTH, T., quoted by SAVARIAUD, W. (1902), *Rev. Chir. Par.*, **26**, 350.  
 GIRARD, C. (1895), *Congrès Franc. de Chir.*, **9**, 823.  
 GORDON-TAYLOR, G., and WILES, P. (1935), *Brit. J. Surg.*, **22**, 671.  
 GORDON-TAYLOR, G., and PATEY, D. H. (1946), *Brit. J. Surg.*, **34**, 61.  
 PACK, T. G., and EHRLICH, H. E. (1946), *Ann. Surg.*, **24**, 1.