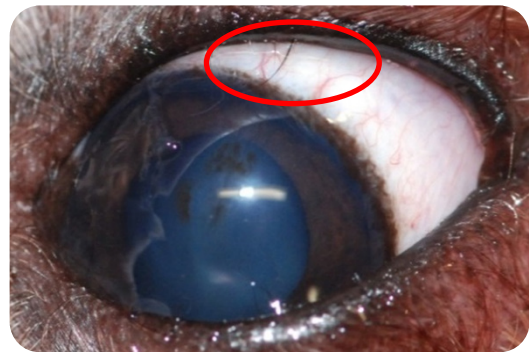
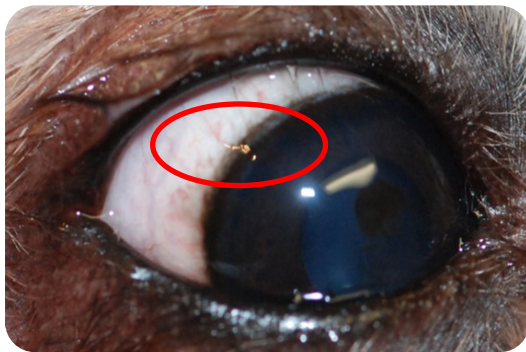


# Distichiasis

Distichia are extra, abnormally positioned hairs (cilia) along the eyelid margin. These cilia can cause irritation to the eye because they are directed toward, instead of away from the eye surface. Many dogs go through life with distichia hairs and if few in number, usually cause minimal to no problems. Eyes irritated by distichia usually have intermittent or persistent redness, squinting, and increased tearing and are prone to corneal ulceration and scarring. When distichia are identified to be causing ocular irritation, the hairs should be removed so they do not cause permanent damage to the cornea.




There are a numerous surgical techniques available to remove distichia. The most common include cryoepilation, electrolysis, and surgical removal of small strips of conjunctiva containing distichia follicles. All these techniques are done under a short general anesthesia.

- 🐾 Cryoepilation involves freezing distichia follicles in the eyelid margin with an ophthalmic cryosurgical unit. This technique is especially beneficial when several distichia are present, and is associated with the most predictable healing post-operatively. Side effects include temporary swelling of the eyelid and depigmentation (pigment loss) of the eyelid margins. Repigmentation of the eyelid margins is usually complete within 4-6 months of surgery. Cryoepilation is effective in destroying 75-85% of hair follicles in a single treatment. In dogs with numerous distichia, and especially those under 2 yrs of age, more hairs can grow following surgery. In these cases, a second surgical procedure is required to relieve irritation from new hairs.



- 🐾 Electrolysis involves burning distichia follicles in the eyelid margin with an ophthalmic electrolytic unit. This technique is especially beneficial when several distichia are present, and is associated with the most predictable healing post-operatively. There is no major side effect. Electrolysis is effective in destroying 75-85% of hair follicles in a single treatment. In dogs with numerous distichia, and especially those under 2 years of age, more hairs can grow following surgery. In these cases, a second surgical procedure is required to relieve irritation from new hairs.



Electrolysis tip: a very thin metallic tip that can be inserted in the base of the hair follicle.

- 🐾 The surgical alternative consists in removing a strip of the palpebral conjunctiva that contains the hair follicles. This technique is especially beneficial when several distichia are present. This technique is more invasive but it is effective in destroying most of hair follicles in a single treatment.

**Dr. Franck Ollivier**, DMV, Ph.D, DACVO and DECVO  
Specialist in veterinary ophthalmology (FR)