

Case Report

***Rhodotorula mucilaginosa* Fungemia, a Rare Opportunistic Infection without Central Venous Catheter Implantation, Successfully Treated by Liposomal Amphotericin B**

Ryuichi Hirano ^{1,2}, Tatsuro Mitsuhashi ¹, and Katsuyoshi Osanai ¹

¹Division of Infection Control, Aomori Prefectural Central Hospital, 2-1-1 Higashi-tsukurimichi, Aomori, Japan, Postal Code:030-8553

²Division of Pharmacy, Aomori Prefectural Central Hospital, 2-1-1 Higashi-tsukurimichi, Aomori, Japan, Postal Code:030-8553

Correspondence should be addressed to Ryuichi Hirano; r.hirano1115@gmail.com

Received 28 November 2021; Revised 4 May 2022; Accepted 19 May 2022; Published 3 June 2022

Academic Editor: Annac Skiada

Copyright © 2022 Ryuichi Hirano et al. This is an open access article distributed under the Creative Commons Attribution License, which permits unrestricted use, distribution, and reproduction in any medium, provided the original work is properly cited.

Background. Fungemia due to *Rhodotorula mucilaginosa* is rare and highly resistance to antifungal therapy. Since most cases of *R. mucilaginosa* fungemia are attributed to medical devices, limited information is currently available on infection without central venous catheter (CVC) implantation. We herein report a case of *R. mucilaginosa* fungemia without implantation of CVC, successfully treated by liposomal amphotericin B (L-AMB). **Case Presentation.** An 81-year-old man with a history of chronic obstructive lung disease and rheumatoid arthritis was admitted with dyspnea and fever. The present case had no previous history of CVC implantation. Candidemia was suspected based on yeast and salmon-pink colonies in blood cultures, and thus, micafungin (MCFG) was administered. The isolated yeast was identified as *R. mucilaginosa*, which exhibited resistance to MCFG. Therefore, antifungal therapy was changed to L-AMB. The sterile blood culture and defervescence were observed from the initiation of L-AMB. **Conclusion.** Although the obvious entry point was unclear, long-term immunosuppressive therapy for RA may have damaged the gastrointestinal tract, which leading to the bacterial translocation of *R. mucilaginosa*. An early class switch to L-AMB was effective. Physicians need to consider the administration of L-AMB in cases suspected of *R. mucilaginosa* fungemia following the detection of salmon-pink colonies in blood cultures.

1. Introduction

Rhodotorula species are commensal yeasts with similar bacteriological characteristics to Cryptococcaceas [1]. These species have been isolated from a number of medical devices, including flexible bronchoscopes and central venous catheter (CVC) tips, due to their strong affinity for plastics and high biofilm-forming ability [2–4]. Salmon-pink colonies are a microscopic characteristic of these species [1]. *Rhodotorula* species are less virulent than *Candida* species but have been reported to cause fungemia in patients with immunodeficiency as well as malignancy [5]. Catheter-related bloodstream infections (CRBSI) are some of the most common infections caused by *Rhodotorula* species, in addition to meningitis and endophthalmitis [1, 5]. Although

the removal of CVC is beneficial for patients with CRBSI due to *Rhodotorula* species, there have been few reports among patients without implantation of CVC [6]. We herein report a case of *R. mucilaginosa* fungemia without CVC that was successfully treated by liposomal amphotericin B (L-AMB).

2. Case Presentation

An 81-year-old man with a history of chronic obstructive lung disease (COPD) and rheumatoid arthritis (RA) was admitted to our hospital with dyspnea, cough, and fever. The patient was receiving prednisolone 5 mg/day, salazosulfa-pyridine 1000 mg/day, and clarithromycin 400 mg/day for COPD and RA. His vital signs were as follows: blood pressure 142/119 mmHg, body temperature 37.7°C,

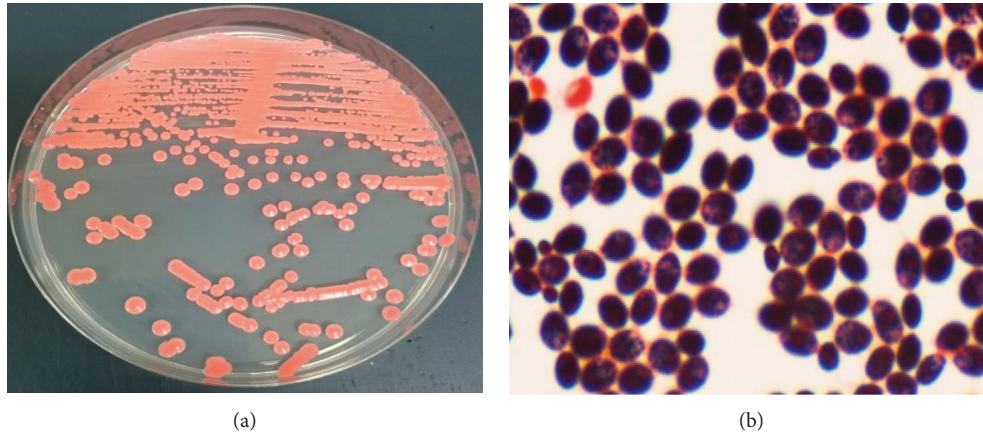


FIGURE 1: (a) *Rhodotorula mucilaginosa* colonies in Sabrouaud medium. (b) Gram stain of the isolate from blood culture.

TABLE 1: Minimal inhibitory concentration and susceptibility pattern for *Rhodotorula mucilaginosa* isolated from a blood culture.

Antifungal agents	Minimum inhibitory concentration ($\mu\text{g/mL}$)
Amphotericin B	0.25
Fluconazole	64
Itraconazole	4
Micafungin	16
Voriconazole	2
Caspofungin	8

respiratory rate 20 breaths/min, and arterial oxygen saturation 88% (4L). Chest X-ray showed decreased permeability in the lungs, and an infiltrative shadow was detected on chest computed tomography. Laboratory findings at admission were as follows: white blood cell count 9,100/ mm^3 , C-reactive protein 12.7 mg/dL, procalcitonin 0.14 ng/mL, serum creatinine 0.62 mg/dL, serum potassium 3.7 mEq/L, and serum (1 \rightarrow 3)- β -D glucan 18.1 pg/mL. The patient was diagnosed with the acute exacerbation of COPD based on pneumonia, and meropenem (MEPM) and methylprednisolone were administered from day 1. *Pseudomonas aeruginosa* and *Haemophilus influenzae* were isolated from a sputum culture submitted at admission. Candidemia was suspected based on yeast and salmon-pink colonies in a blood culture submitted at admission (Figure 1), and thus, micafungin (MCFG) 150 mg QD was administered from day 6. No findings suggestive of endophthalmitis were observed based on an ophthalmological examination. On day 8, the yeast isolated from the blood culture was identified as *Rhodotorula* species according to the VITEK 2 YST ID Card (SYSMEX; bio-Merieux, Lyon, France). An antifungal susceptibility test was performed using the yeast-like fungal drug susceptibility kit ASTY (Kyokuto Pharmaceutical Industrial, Tokyo, Japan). The minimum inhibitory concentrations of each antifungal agent are shown in Table 1. According to the guidelines, *Rhodotorula* species are considered to be intrinsically resistant to azoles and echinocandins [6]. The isolated yeast was identified as *R. mucilaginosa* by a sequencing analysis of ITS and the D1/D2 region of ribosomal DNA using

panfungal primers [7, 8]. Based on these findings, the patient was diagnosed with fungemia due to *R. mucilaginosa*, and antifungal therapy was changed from MCFG to L-AMB 3 mg/kg QD on day 8. In addition to defervescence, a sterile blood culture was noted on day 10. Due to a decrease in the serum level of potassium to 2.6 (mEq/L), potassium supplementation was initiated on day 17. The serum level of potassium increased to 4.3 (mEq/L) by day 23. L-AMB therapy was continued for 17 days and no increase in the serum level of creatinine was observed. The patient was discharged on day 64 with no signs of relapse of the infection.

3. Discussion

We herein described a case of fungemia due to *R. mucilaginosa* that was successfully treated with L-AMB. Although *R. mucilaginosa* fungemia is a rare opportunistic infection, it is the fourth most common causative species of fungemia, except for *Candida* species [9]. In addition to their high resistance to antifungal agents, *Rhodotorula* species cause approximately 50% of cases of non-*Candida* and *Cryptococcus* fungemia in patients with malignancy [10]. Therefore, further information is needed to manage this fungal infection, particularly in immunocompromised hosts.

A previous study identified *R. mucilaginosa* as the most common species causing fungemia due to *Rhodotorula* species [11]. The overall mortality rate was approximately 12% [11]. Malignancy, autoimmune disease, immunosuppressive therapy, and corticosteroid use have been identified as risk factors for the onset of fungemia due to *Rhodotorula* species [1, 5]. The present case had received prednisolone and salazosulfapyridine to treat RA, which may have been the causative factor for the onset of *R. mucilaginosa* fungemia. Although the implantation of CVC has been reported as the most common risk factor for fungemia due to *R. mucilaginosa*, the present case had no previous history of CVC implantation [1, 5, 12]. Besides CVC, bacterial translocation associated with an injured gastrointestinal tract is an entry point for *R. mucilaginosa*, a gastrointestinal bacterium that resides in the colon [1]. Although the obvious

entry point was unclear in the present case, long-term immunosuppressive therapy for RA may have damaged the gastrointestinal tract, leading to the bacterial translocation of *R. mucilaginosa*.

In the present case, serum (1→3)- β -D glucan was 18.1 pg/mL, which was not significantly elevated despite fungemia. The results obtained in the present case were consistent with previous findings showing no increase in serum (1→3)- β -D glucan at the onset of fungemia due to *R. mucilaginosa* [13]. The fungal characteristics of *Rhodotorula* species are similar to those of *Cryptococcus* species. Among patients with *Cryptococcus* fungemia, (1→3)- β -D glucan did not increase because the cell wall of *Cryptococcus* species comprises (1→6)- β -D glucan [13]. The composition of the cell wall of *R. mucilaginosa* may contribute to the lack of an increase in serum (1→3)- β -D glucan in patients with *R. mucilaginosa* fungemia; however, the underlying mechanisms have not yet been elucidated in detail. Further studies on serum (1→3)- β -D glucan levels in *R. mucilaginosa* fungemia are warranted because limited information is currently available on this biomarker at the onset of disease. The present case supports the importance of blood culture tests for patients suspected of invasive fungal infection.

R. mucilaginosa isolated from the present case was resistant to echinocandins, e.g., MCFG and CPGF, whereas it seemed to be susceptible to AMB. Susceptibility patterns in the present case were consistent with the findings of previous antifungal susceptibility surveillance for *Rhodotorula* species [14]. An early class switch to L-AMB contributed to bacterial clearance and defervescence in the present case because *Rhodotorula* species are intrinsically resistant to azoles and echinocandins [6].

Fungemia due to *R. mucilaginosa* has been defined as a rare fungal infection according to the guidelines of the European Society of Clinical Microbiology and Infectious Disease (ESCMID) [15]. According to the latest guidelines, AMB preparations are the preferred treatment option based on susceptibility patterns, and source control, e.g., the removal of CVC is strongly recommended in patients with a CVC implanted [6]. In the present case, there were no sites of infection that needed removal because a CVC was not implanted. Therefore, the administration of L-AMB was essential for treatment.

Regarding the present case, laboratories with limited experience in mycology may not be aware that pink colonies are not a characteristic of *Candida* species, which results in a delay in the initiation of L-AMB therapy. *Rhodotorula* and *Sporobolomyces* species both form characteristic pink colonies, and the guidelines recommended the avoidance of echinocandin therapy for patients with suspected infections by these yeasts [6]. Fortunately, the delay in initiating L-AMB therapy did not adversely affect the outcome of the present case. This may be attributed to the lower virulence of *R. mucilaginosa* than that of more common fungal pathogens, e.g., *Candida* species [5]. The present case supports the importance of alerting physicians of expected susceptibility patterns in patients with laboratory results showing the characteristic colony findings of yeasts.

Hypokalemia and renal dysfunction have been reported as severe side effects of L-AMB [16]. Potassium supplementation is essential for the prevention of hypokalemia because of its high frequency during the administration of L-AMB [17]. In the present case, close monitoring and potassium supplementation effectively prevented the development of hypokalemia during L-AMB therapy. There is currently no established duration for antifungal therapy in patients with *R. mucilaginosa* fungemia. The present case received L-AMB therapy for 14 days after the confirmation of a sterile blood culture test, in accordance with a previous study [18].

4. Conclusion

We herein report a case of fungemia due to *R. mucilaginosa* that was successfully treated by L-AMB. Although the obvious entry point was unclear, immunosuppressive therapy with RA potentially damaged the gastrointestinal tract, which may have resulted in the bacterial translocation of *R. mucilaginosa*. Physicians need to consider the administration of L-AMB in immunocompromised cases suspected of *R. mucilaginosa* fungemia following the detection of salmon-pink colonies in blood cultures.

Data Availability

No data were used to support this study.

Consent

Written informed consent for publication was obtained from the patient.

Conflicts of Interest

The authors declare that there are no conflicts of interest regarding the publication of this article.

Authors' Contributions

KO and RH collected the clinical data. RH drafted the manuscript. TM helped write and revise the manuscript. All authors read and approved the final manuscript.

References

- [1] L. W. Lunardi, V. R. Aquino, R. A. Zimmerman, and L. Z. Goldani, "Epidemiology and outcome of *Rhodotorula* fungemia in a tertiary care hospital," *Clinical Infectious Diseases*, vol. 43, no. 6, pp. 60–63, 2006.
- [2] M. E. Hagan, S. A. Klotz, W. Bartholomew, L. Potter, and M. Nelson, "A pseudoepidemic of *Rhodotorula rubra*: a marker for microbial contamination of the bronchoscope," *Infection Control and Hospital Epidemiology*, vol. 16, no. 12, 1995.
- [3] V. Silva, G. Zepeda, M. E. Rybak, and N. Febre, "Yeast carriage on the hands of Medicine students," *Revista Iberoamericana De Micologia*, vol. 20, no. 2, 2003.
- [4] J. M. Nunes, F. C. Bizerra, R. C. e Ferreira, and A. L. Colombo, "Molecular identification, antifungal susceptibility profile,

- and biofilm formation of clinical and environmental *Rhodotorula* species isolates,” *Antimicrobial Agents and Chemotherapy*, vol. 57, no. 1, 2013.
- [5] P. Ioannou, R. Vamvoukaki, and G. Samonis, “*Rhodotorula* species infections in humans: a systematic review,” *Mycoses*, vol. 62, no. 2, pp. 90–100, 2019.
 - [6] S. C. A. Chen, J. Perfect, A. L. Colombo et al., “Global guideline for the diagnosis and management of rare yeast infections: an initiative of the ECMM in cooperation with ISHAM and ASM,” *The Lancet Infectious Diseases*, vol. 21, no. 12, 2021.
 - [7] K. O’Donnell, “*Fusarium* and its near relatives,” *The Fungal Holomorph: Mitotic, Meiotic and Pleomorphic Speciation in Fungal Systematics*, CAB International, Wallingford, UK, 1993.
 - [8] T. J. White, T. Bruns, S. Lee, and J. W. Taylor, “Amplification and direct sequencing of fungal ribosomal rna genes for phylogenetics,” *PCR Protocols: A Guide to Methods and Applications*, Academic Press, Cambridge, MA, USA, 1990.
 - [9] M. A. Pfaller, D. J. Diekema, D. L. Gibbs et al., “Results from the ARTEMIS DISK global antifungal surveillance study, 1997 to 2005: an 8.5-year analysis of susceptibilities of *Candida* species and other yeast species to fluconazole and voriconazole determined by CLSI standardized disk diffusion testing,” *Journal of Clinical Microbiology*, vol. 45, no. 6, 2007.
 - [10] M. N. Chitasombat, D. P. Kofteridis, Y. Jiang, J. Tarrand, R. E. Lewis, and D. P. Kontoyiannis, “Rare opportunistic (non-*Candida*, non-*Cryptococcus*) yeast bloodstream infections in patients with cancer,” *Journal of Infection*, vol. 64, no. 1, 2012.
 - [11] F. F. Tuon, S. F. Costa, and “*R. infection*,” “*Rhodotorula* infection. A systematic review of 128 cases from literature,” *Revista Iberoamericana De Micologia*, vol. 25, no. 3, 2008.
 - [12] A. Spiliopoulou, E. D. Anastassiou, and M. Christofidou, “*Rhodotorula* fungemia of an intensive care unit patient and review of published cases,” *Mycopathologia*, vol. 174, no. 4, 2012.
 - [13] T. Kitazawa, S. Ishigaki, K. Seo, Y. Yoshino, and Y. Ota, “Catheter-related bloodstream infection due to *Rhodotorula mucilaginosa* with normal serum (1→3)- β -D-glucan level,” *Journal de Mycologie Médicale*, vol. 28, no. 2, 2018.
 - [14] D. J. Diekema, B. Petroelje, S. A. Messer, R. J. Hollis, and M. A. Pfaller, “Activities of available and investigational antifungal agents against *Rhodotorula* species,” *Journal of Clinical Microbiology*, vol. 43, no. 1, 2005.
 - [15] M. C. Arendrup, T. Boekhout, M. Akova, J. F. Meis, O. A. Cornely, and O. Lortholary, “ESCMID† and ECMM‡ joint clinical guidelines for the diagnosis and management of rare invasive yeast infections,” *Clinical Microbiology and Infection*, vol. 20, 2014.
 - [16] H. Yamazaki, T. Kondo, K. Aoki, K. Yamashita, and A. Takaori-Kondo, “Occurrence and improvement of renal dysfunction and serum potassium abnormality during administration of liposomal amphotericin B in patients with hematological disorders: a retrospective analysis,” *Diagnostic Microbiology and Infectious Disease*, vol. 90, no. 2, 2018.
 - [17] E. Usami, M. Kimura, T. Kanematsu et al., “Evaluation of hypokalemia and potassium supplementation during administration of liposomal-amphotericin B,” *Experimental and Therapeutic Medicine*, vol. 7, no. 4, 2014.
 - [18] M. R. Capoor, S. Aggarwal, C. Raghvan, D. K. Gupta, A. K. Jain, and R. Chaudhary, “Clinical and microbiological characteristics of *Rhodotorula mucilaginosa* infections in a tertiary-care facility,” *Indian Journal of Medical Microbiology*, vol. 32, no. 3, 2014.