

## Mass Mortality of Green Frog (*Rana clamitans*) Tadpoles in Wisconsin, USA, Associated with Severe Infection with the Pathogenic Perkinsea Clade

Marcos Isidoro-Ayza,<sup>1,4</sup> Jeffrey M. Lorch,<sup>2</sup> Anne E. Ballmann,<sup>2</sup> and Nancy K. Businga<sup>3</sup> <sup>1</sup>Department of Pathobiological Sciences, School of Veterinary Medicine, University of Wisconsin, 2015 Linden Drive, Wisconsin 53706, USA; <sup>2</sup>National Wildlife Health Center, US Geological Survey, 6006 Schroeder Road, Madison, Wisconsin 53711, USA; <sup>3</sup>Wisconsin Department of Natural Resources, 2801 Progress Road, Madison, Wisconsin 53716, USA; <sup>4</sup>Corresponding author (email: isidoroayza@wisc.edu)

**ABSTRACT:** We documented mortality of green frog (*Rana clamitans*) tadpoles in Wisconsin, US, attributed to severe Perkinsea infection. Final diagnosis was determined by histopathology, followed by molecular detection of pathogenic Perkinsea clade (PPC) of frogs in the liver. To our knowledge, this represents the first detection of PPC in the midwestern US.

Severe Perkinsea infection (SPI) is an emerging disease of frogs responsible for mass mortalities of tadpoles across the US (Davis et al. 2007; Landsberg et al. 2013; Chambouvet et al. 2015; Isidoro-Ayza et al. 2017). It is caused by a pathogenic lineage of protozoa with a direct life cycle belonging to the Novel Alveolate Group 01 of the phylum Perkinsozoa (superphylum Alveolata; Chambouvet et al. 2015), tentatively named pathogenic Perkinsea clade (PPC) of frogs (Isidoro-Ayza et al. 2017).

To date, SPI has been diagnosed in 12 US states. Most SPI events have occurred in states bordering the Atlantic Ocean and Gulf of Mexico (Davis 2009; Landsberg et al. 2013; Isidoro-Ayza et al. 2017). However, SPI has also been detected on the West Coast (Alaska and Oregon) and in the Upper Midwest (Minnesota) of the US (Isidoro-Ayza et al. 2017). Outbreaks often exhibit local recurrence (Isidoro-Ayza et al. 2017).

Molecular confirmation of PPC as the causative agent of SPI has been demonstrated in tadpoles from the East Coast, Gulf of Mexico, and the West Coast (Chambouvet et al. 2015; Isidoro-Ayza et al. 2017). The lack of available frozen tissues from SPI tadpoles collected during the outbreak in Minnesota

prevented molecular confirmation of PPC in the midwest US.

A mortality event involving approximately 1,200 to 1,500 tadpoles was reported at Lake Laura, Vilas County, Wisconsin, US (46°3'17"N; 89°26'15"W) between 11 June 2017 and 8 August 2017. Initially, an average of 20 to 30 sick or dead tadpoles was observed daily on the bottom of the lake or along the shoreline. Sick tadpoles were lethargic or swimming erratically in circles or upside down. By late July, the daily number of sick or dead tadpoles decreased to an average of 5 to 10. No adults were found sick or dead. Most tadpoles were identified in the field as green frogs (*Rana clamitans*), with a few suspected northern leopard frogs (*Rana pipiens*). No other sympatric amphibians were involved during this mortality event.

The Wisconsin Department of Natural Resources, with the help of local residents, collected and submitted 17 tadpoles to the US Geological Survey, National Wildlife Health Center for postmortem investigation. Nine tadpoles were submitted frozen in separate plastic bags; five were submitted fixed in 70% ethanol; and three were shipped fixed in 10% buffered neutral formalin.

Seven of the frozen tadpoles were thawed upon arrival and prosected. Anuran life stage (Gosner 1960) and species (Powell et al. 2016) were determined on the basis of the external morphologic features. Tadpoles ranged from late hatchling (Gosner stage 25) to late larvae (Gosner stage 41) developmental stages (Table 1). All tadpoles examined were in fair to good postmortem preservation state (early decomposition to freshly preserved, respec-

TABLE 1. Physical measurements and postmortem study results of 17 green frog (*Rana clamitans*) tadpoles found dead at Lake Laura, Wisconsin, USA, in 2017 and tested for diseases, including pathogenic Perkinsea clade of frogs.

| Tadpole identification | Carcass preservation | Gosner stage <sup>a</sup> | PPS <sup>b</sup> | BC <sup>c</sup> | Histo-SPI <sup>d</sup> | PPC <sup>e</sup> | Bd <sup>f</sup> | VI <sup>g</sup> |
|------------------------|----------------------|---------------------------|------------------|-----------------|------------------------|------------------|-----------------|-----------------|
| 1                      | Frozen               | 31                        | Good             | Good            | NA                     | NA               | NA              | No              |
| 2                      | Frozen               | 39                        | Good             | Good            | NA                     | NA               | NA              | No              |
| 3                      | Frozen               | 41                        | Good             | Good            | NA                     | NA               | NA              | No              |
| 4                      | Frozen               | 41                        | Good             | Good            | Yes                    | Yes              | No              | No              |
| 5                      | Frozen               | 41                        | Good             | Good            | Yes                    | Yes              | No              | No              |
| 6                      | Frozen               | 40                        | Good             | Good            | Yes                    | Yes              | No              | No              |
| 7                      | Frozen               | 41                        | Fair             | Good            | Yes                    | Yes              | No              | No              |
| 8                      | Frozen               | NA <sup>h</sup>           | NA               | NA              | NA                     | NA               | NA              | NA              |
| 9                      | Frozen               | NA                        | NA               | NA              | NA                     | NA               | NA              | NA              |
| 10                     | 70% ethanol          | NA                        | NA               | NA              | Yes                    | NA               | NA              | NA              |
| 11                     | 70% ethanol          | NA                        | NA               | NA              | Yes                    | NA               | NA              | NA              |
| 12                     | 70% ethanol          | NA                        | NA               | NA              | Yes                    | NA               | NA              | NA              |
| 13                     | 70% ethanol          | NA                        | NA               | NA              | na                     | NA               | NA              | NA              |
| 14                     | 70% ethanol          | NA                        | NA               | NA              | na                     | NA               | NA              | NA              |
| 15                     | 10% formaldehyde     | NA                        | NA               | NA              | Yes                    | NA               | NA              | NA              |
| 16                     | 10% formaldehyde     | 25                        | NA               | NA              | Yes                    | NA               | NA              | NA              |
| 17                     | 10% formaldehyde     | 25                        | NA               | NA              | Yes                    | NA               | NA              | NA              |

<sup>a</sup> Gosner stage = tadpole life stage (Gosner 1960).

<sup>b</sup> PPS = postmortem preservation state.

<sup>c</sup> BC = body condition based on presence (good) or absence (poor) of fat bodies.

<sup>d</sup> Histo-SPI = histologic diagnosis of severe Perkinsea infection.

PPC = PCR detection followed by identification of pathogenic Perkinsea clade of frogs by sequencing of the small subunit (18S) rDNA (Chambouvet et al. 2015).

<sup>f</sup> Bd = PCR detection of *Batrachochytrium dendrobatidis* (Bloom et al. 2013).

<sup>g</sup> VI = viral isolation in fathead minnow (*Pimephales promelas*) cell line from pooled liver, kidney, and spleen (tadpole nos. 1–3) or pooled liver and kidney (tadpole nos. 4–7; Miller et al. 2015).

<sup>h</sup> NA = not applicable.

tively) and were in good body condition on the basis of the presence of fat bodies in the coelomic cavity (Table 1). Gross lesions observed included ascites (seven of seven), hepatomegaly (seven of seven) nephromegaly (four of seven), splenomegaly (two of seven), segmental irregular thickening and white discoloration of the intestine (three of seven), and randomly distributed areas of white skin discoloration (two of seven). Gastrointestinal content was abundant and apparently normal in six of seven tadpoles. The gastrointestinal tract of the remaining tadpole was empty. Pooled liver, kidney, and spleen of three tadpoles and pooled liver and kidney of four tadpoles were collected in viral transport medium and cultured in confluent monolayers of fathead minnow (*Pimephales promelas*) cell line to test for presence of *Ranavirus* (Miller

et al. 2015). No cytopathic effect was observed for any specimen tested (Table 1). The mouth parts of four tadpoles were swabbed and using a duplex real-time PCR (Bloom et al. 2013), tested negative for *Batrachochytrium dendrobatidis* and *Batrachochytrium salamandrivorans* (Table 1). A complete set of organs from four of the seven frozen tadpoles were collected in 10% formalin and processed for histopathology. The same organs from three tadpoles received in 70% ethanol and the three received in 10% formaldehyde were also processed for histopathology. All tadpoles presented extensive necrosis in multiple organs and replacement of preexisting tissues with myriad Perkinsea-like organisms (Fig. 1), as previously described (Davis et al. 2007; Landsberg et al. 2013; Isidoro-Ayza et al. 2017). The most extensively affected organs

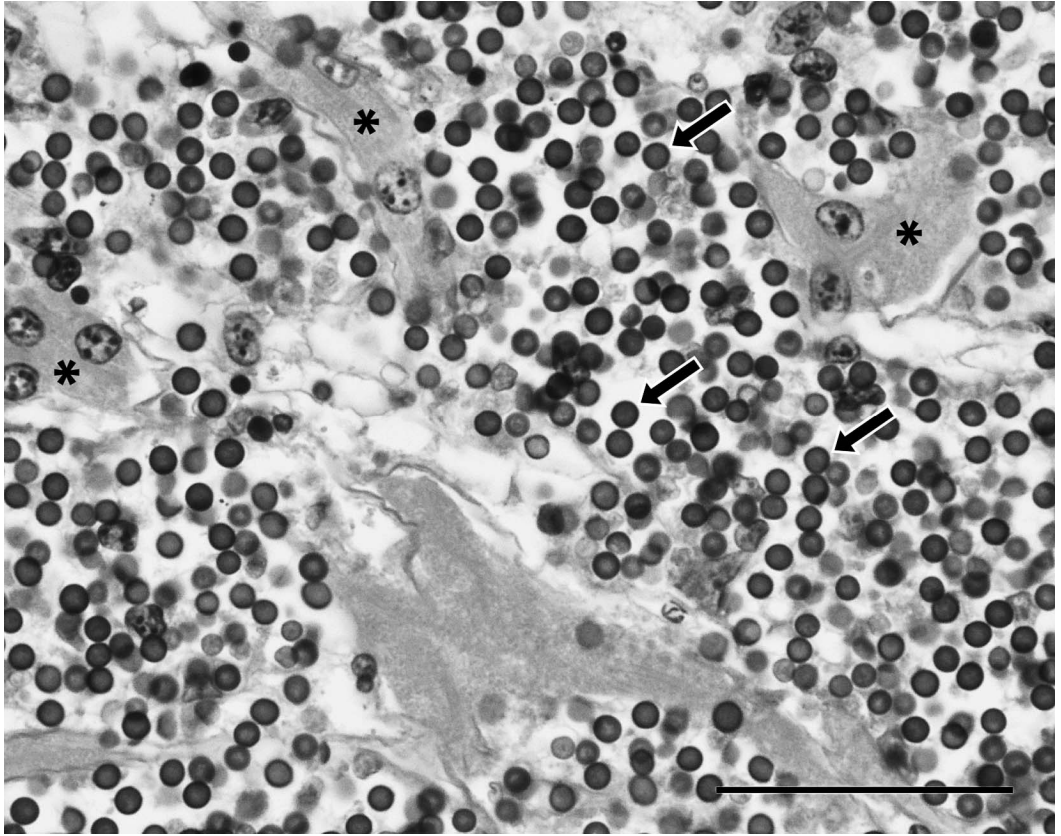


FIGURE 1. Photomicrograph of H&E-stained section of liver from green frog (*Rana clamitans*) tadpole no. 11, diagnosed with severe *Perkinsella* infection from an outbreak in Wisconsin, USA, in 2017. Numerous *Perkinsella*-like organisms (arrows) replace the hepatocytes (asterisks) and efface the hepatic architecture (bar=50  $\mu$ m).

were liver, spleen, and kidney. In addition, one or more of the following tissues were affected but to a lesser extent: cartilage, central nervous system, gastrointestinal tract, gills, gonads, heart, pancreas, peritoneum, skeletal muscle, skin, and thyroid glands.

Frozen liver from four tadpoles with histologic confirmation of SPI were thawed and processed for PCR amplification and sequencing of PPC (Chambouvet et al. 2015; Isidoro-Ayza et al. 2017). The PPC DNA was amplified and identified from all four tadpoles by using the Basic Local Alignment Search Tool algorithm (National Center for Biological Information 2017).

On the basis of these findings, SPI was considered the most likely cause of this mortality event. To our knowledge, this is

the first reported outbreak of SPI in Wisconsin and the first time that PPC has been linked to SPI in the midwestern US. Further monitoring and reporting of SPI is paramount to better understand the ecology, epidemiology, and deleterious effects of this emerging disease on wild anuran populations.

We recognize the invaluable field assistance of Amy Hermus and the Lake Laura private citizens who reported the mortality event, collected samples, and provided important field observations through their conscientious monitoring of their lake resource. We acknowledge technical assistance provided by personnel of the US Geological Survey, National Wildlife Health Center and the Wisconsin Department of Natural Resources Bureaus of Natural Heritage Conservation

and Wildlife Management and the financial support for amphibian diagnostics provided by the US Geological Survey's Amphibian Research and Monitoring Initiative (USGS-ARMI). This is USGS-ARMI contribution 619.

#### LITERATURE CITED

- Blooi M, Pasmans F, Longcore JE, Spitzen-van der Sluijs A, Vercammen F, Martel A. 2013. Duplex real-time PCR for rapid simultaneous detection of *Batrachochytrium dendrobatidis* and *Batrachochytrium salamandrivorans* in amphibian samples. *J Clin Microbiol* 51:4173–4177.
- Chambouvet A, Gower DJ, Jirků M, Yabsley MJ, Davis AK, Leonard G, Maguire F, Doherty-Bone TM, Bittencourt-Silva GB, Wilkinson M, et al. 2015. Cryptic infection of a broad taxonomic and geographic diversity of tadpoles by *Perkinsea* protists. *Proc Natl Acad Sci U S A* 112:E4743–E4751.
- Davis AK, Yabsley MJ, Keel MK, Maerz JC. 2007. Discovery of a novel alveolate pathogen affecting southern leopard frogs in Georgia: Description of the disease and host effects. *EcoHealth* 4:310–317.
- Gosner KL. 1960. A simplified table for staging anuran embryos and larvae with notes on identification. *Herpetologica* 16:183–190.
- Isidoro-Ayza M, Lorch JM, Gear DA, Winzeler M, Calhoun DL, Barichivich WJ. 2017. Pathogenic lineage of *Perkinsea* associated with mass mortality of frogs across the United States. *Sci Rep* 7:10288.
- Landsberg JH, Kiryu Y, Tabuchi M, Waltzek TB, Enge KM, Reintjes-Tolen S, Preston A, Pessier AP. 2013. Co-infection by alveolate parasites and frog virus 3-like ranavirus during an amphibian larval mortality event in Florida, USA. *Dis Aquat Organ* 105:89–99.
- Miller DL, Pessier AP, Hick P, Whittington RJ. 2015. Comparative pathology of ranaviruses and diagnostic techniques. In: *Ranaviruses: Lethal pathogens of ectothermic vertebrates*, Gray MJ, Chinchir VG, editors. Springer, Cham, Switzerland, pp. 171–208.
- National Center for Biological Information. 2017. *Basic local alignment search tool (BLAST)*. <http://blast.ncbi.nlm.nih.gov/Blast.cgi>. Accessed September 2017.
- Powell R, Conant R, Collins, JT. 2016. *Peterson field guide to reptiles and amphibians of Eastern and Central North America*, 4th Ed. Houghton Mifflin Harcourt, New York, New York, 492 pp.

*Submitted for publication 16 February 2018.*

*Accepted 11 May 2018.*