

A rare case of uterine didelphys

Sudha R^{1*}, Sunanda N², Babitha M C³

¹Associate Professor, ²Assisant Professor, ³Postgraduate, Department of OBGY, MMCRI, Mysore, Karnataka, INDIA.

Email: drsudhaobgmmcri@gmail.com

Abstract

Uterus didelphys is one of the congenital uterine anomalies due to defective medial fusion of Mullerian ducts. Often remains asymptomatic and hence undetected. Women with congenital uterine alformation usually have higher incidence of complications during pregnancy and delivery. Although pregnancies can occur in patients with Mullerian duct anomalies, most of them have been linked to infertility, recurrent pregnancy loss, pre term deliveries, fetal mal-presentations and other obstetrics complications, making successful pregnancy outcome a rare situation in this condition. We report a case of successful pregnancy outcome in a case of uterus didelphys bicollis. A 25year old P2L2 with 2 previous LSCS, failed LS, with 2 months of amenorrhea, continued her pregnancy till term and underwent cesarean section with concurrent sterilization.

Keywords: uterine didelphys, pregnancy

*Address for Correspondence:

Dr. Sudha R., Associate Professor, Department of OBGY, MMCRI, Mysore, Karnataka, INDIA.

Email: drsudhaobgmmcri@gmail.com

Received Date: 12/03/2019 Accepted Date: 13/05/2019

Access this article online

Quick Response Code:	Website: www.statperson.com
	Volume 9 Issue 3

INTRODUCTION

PAPER: Mrs. X, 25 yr old, a resident of K R nagara presented as P2L2 with 2 previous LSCS, sterilized 2 years back, with 2 months of amenorrhea.

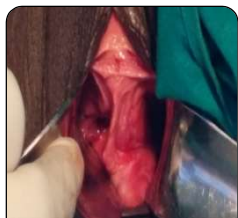

Figure 1: On examination: uterus was 12 weeks size, soft cervix, longitudinal vaginal septum was seen

USG revealed a pregnancy of 12 weeks duration. Patient opted for continuation of pregnancy. She was married for 8 years. She did not conceive for 3 years for which she was investigated with USG and found to have uterus

didelphys in august 2008. First pregnancy: Conceived spontaneously, she underwent Emergency cesarean section, indication being fetal distress with IUGR on 4/8/2009. Per op: uterine didelphys with vaginal septum. Baby was term, 1.9kg, IUGR, single umbilical artery and genu recurvatum which was corrected. Now the baby is 4 yrs old, alive and healthy. No contraception used.

Second Pregnancy

She conceived a year later spontaneously. Underwent Emergency LSCS for preterm premature rupture of membranes with previous LSCS and delivered a 1.5 kg male baby, the baby is 3 yrs old, alive and healthy. Underwent Laparoscopic sterilization in 2011 in which left tube was not visualized. Patient was conveyed the same and advised to come for follow up.

Third pregnancy

Conceived 2 yrs later. The lady continued her present pregnancy till term and underwent cesarean section, delivered a 1.9 kg term IUGR female baby, with concurrent sterilization. post-operative period uneventful. Both the mother and the baby were healthy.

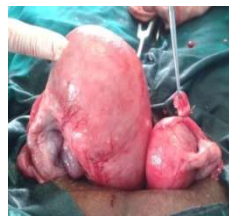

Figure 2: Pregnancy was found in the left horn

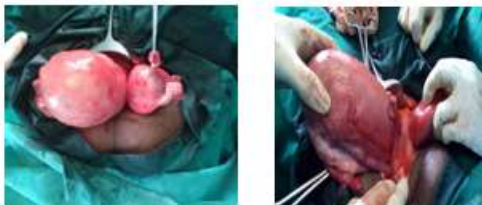

Figure 2A: axial view of the two uterine bodies **Figure 2B:** a septum separating the two

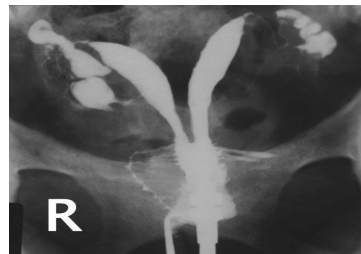

Figure 4: HSG image of uterus didelphys

DISCUSSION

The incidence of mullerian anomalies is 0.1 to 10%^{1,4}. Mullerian duct is formed as an invagination of mesothelium of celomic cavity on ventral part of intermediate cell mass.

Normal development includes:

- Organogenesis
- Fusion
- Septal resorption

American fertility Society classification and Modified Rock and Adam - AFS classification are the two systems used for classification^{2,6}. Didelphic Uterus is a rare condition in which there is complete failure of fusion of mullerian ducts. Occurs in 1 in 1500 to 1 in 15000 women. Often remains asymptomatic and hence undetected. Associated with best possibility of successful pregnancy outcome among all the uterine anomalies. Diagnosis by Obstructive symptoms, Difficulty in using tampons, Difficulty in coitus, Symmetrical on palpation per abdomen, Vaginal septum and 2 cervixes on examination³, During MRP, Abnormal uterine contour during pregnancy, Pregnancy occurring despite the presence of IUCD, Persistent Postmenopausal bleed despite D and C, Incidentally on laprotomy, HSG to evaluate infertility⁵. Uterus didelphys may be associated with renal agenesis³. USG, HSG, Hysteroscopy, MRI, are used as the diagnostic modalities.

25% have serious reproductive problems: Poor vascularisation, Distortion of uterine cavity. Incompetent cervix, Luteal phase deficiency, Absence of estrogen leading to Inability to conceive, Abortion, Preterm delivery, Abnormal presentation, Non progression of labour, PPH, Retained placenta. Treatment is indicated when there are repeated pregnancy losses, after correcting extra uterine causes. Various corrective surgeries are performed to unify the uterine cavities; removal of the septum. The reproductive outcome depends on the respective anomaly.

CONCLUSION

Although frequently asymptomatic with possibility of normal pregnancies in patients with Mullerian duct anomalies, all of these congenital anomalies have been associated with Infertility, Recurrent pregnancy loss, Preterm delivery, fetal malpresentation and other obstetric complications, all of which increase perinatal morbidity and mortality rates¹. Successful pregnancy outcome is a rare situation in this condition.

REFERENCES

1. TeLinde’s operative Gynecology- 10th edition
2. Human labour and birth, oxorn-foote- 6th edition
3. Mullerian duct anomalies clinical concept- Elayan A, Saeed A. ASJOG, Volume1, 2004.
4. Humaira R, Sobia N, Nadia S, Asma TU. Frequency of mullerian duct abnormalities. J Rawal Med Coll 2009; 13(1):34-7.
5. Rackow BW, Ar ici A. Reproductive performance of women with mullerian anomalies. Curr Opin Obstet Gynecol. 2007; 19: 229-37.
6. Clinical approach for the classification of congenital uterine malformations, Grigoris F. Grimbizis and Rudi Campo, Gynecol Surg (2012) 9:119–129.

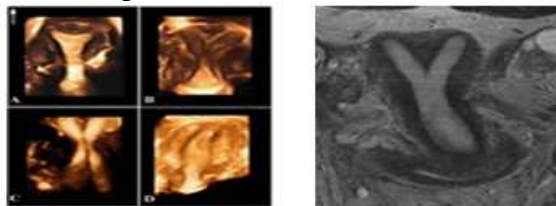


Figure 3A **Figure 3B**
Figure 3A: 3-d Ultrasound images of **A:** normal uterus
Figure 3B: MRI image of a bicornuate uterus. **B:** bicornuate uterus, **C:** uterus didelphys, **D:** Unicornuate uterus.

Source of Support: None Declared
 Conflict of Interest: None Declared