



Case Report

Unsuspected Dematiaceous Fungal Infection Causing Subcutaneous Nodules in a Diabetic Patient

Lauren Fontana¹, Marcel E. Curlin^{2*}

¹Division of Infectious Diseases, University of Minnesota, Minneapolis, MN, USA

²Department of Medicine, Division of Infectious Diseases, Oregon Health and Science University, Portland, USA

***Corresponding author:** Marcel E. Curlin, Department of Medicine, Division of Infectious Diseases, Oregon Health and Science University, Portland, USA

Citation: Fontana L, Curlin ME (2022) Unsuspected Dematiaceous Fungal Infection Causing Subcutaneous Nodules in a Diabetic Patient. Ann Case Report 7: 976. DOI: 10.29011/2574-7754.100976

Received: 29 September 2022, **Accepted:** 03 October 2022, **Published:** 05 October 2022

Abstract

Melanised dematiaceous fungi are environmental saprophytes that can cause subcutaneous phaeohyphomycosis. We describe a case of coincident subcutaneous phaeohyphomycosis due to *Medicopsis romero* and *Cryptococcus neoformans* meningitis in a Cambodian native female with uncontrolled diabetes mellitus and seropositive non-erosive rheumatoid arthritis receiving chronic steroids. Both organisms are dematiaceous environmental fungi but *M. Romero* infrequently causes invasive disease, occurring most commonly in the setting of immune suppression. We discuss the clinical significance, diagnosis and treatment of phaeohyphomycosis in an immunocompromised host.

Case Report

A 65 y/o Cambodian native female, who immigrated to the United States 30 years ago, presented with an 18-month history of persistent painless right knee swelling, and six days of acute fever and progressive confusion. Her medical history included poorly controlled type II diabetes mellitus, and seropositive rheumatoid arthritis (RA) diagnosed two years prior to admission. On initial rheumatologic evaluation, she was prescribed oral methotrexate 15mg weekly for 11 months and prednisone 10mg daily. The prednisone dose was increased to 20mg for ongoing generalized arthralgia one year later. However, ten months after starting therapy, she developed persistent painless right knee swelling, and eight months later experienced new spontaneous drainage from a nodular lesion overlying the patella. A home remedy of vinegar-soaked bread was applied but swelling and drainage persisted. Admission vital signs revealed a fever of 103°C, HR of 110 bpm, BP of 85/51 mmHg, and oxygen saturation of 88% on room air. Examination confirmed confusion without focal neurologic deficits. The right knee was swollen with multiple fluctuant prepatellar lesions (Figure 1, panel A) from which abundant cream-

colored pus was expressed. The serum WBC count was 12 K/mm. Lumbar puncture opening pressure was 22 cm H₂O. Cerebral spinal fluid (CSF) contained 32 WBC with 87% lymphocytes, protein and glucose values of 263mg/dL and 135mg/dL, respectively. CSF *Cryptococcus* antigen was positive (titer 1:320) and fungal culture grew *Cryptococcus neoformans*. Testing for HIV and tuberculosis was negative.

Manually expressed knee drainage revealed 3+ fungal suspected pseudo hyphae (Figure 1, panels D, E). Right knee MRI revealed multiple subcutaneous rim-enhancing prepatellar collections but no knee joint abnormalities (Figure 1, panels B, C). Pathology from a prepatellar bursectomy demonstrated an organizing abscess with surrounding fibrosis, and multinucleated histiocytic. No macroscopic granules were observed. Groote's methoxamine silver stain showed darkly pigmented spores and hyphae within inflammatory zones (Figure 1, panel F). Mucicarmine stain was negative for *Cryptococcus*. Surgical culture revealed fungal hyphae and sequencing of 28S ribosomal DNA yielded a final diagnosis of *Medicopsis romero*. The patient's hospital course was complicated by prolonged encephalopathy

due to Cryptococcal meningitis requiring serial lumbar punctures. She received liposomal amphotericin and flu cytosine for 28 days, followed by consolidation therapy with voriconazole and was ultimately discharged in stable condition.

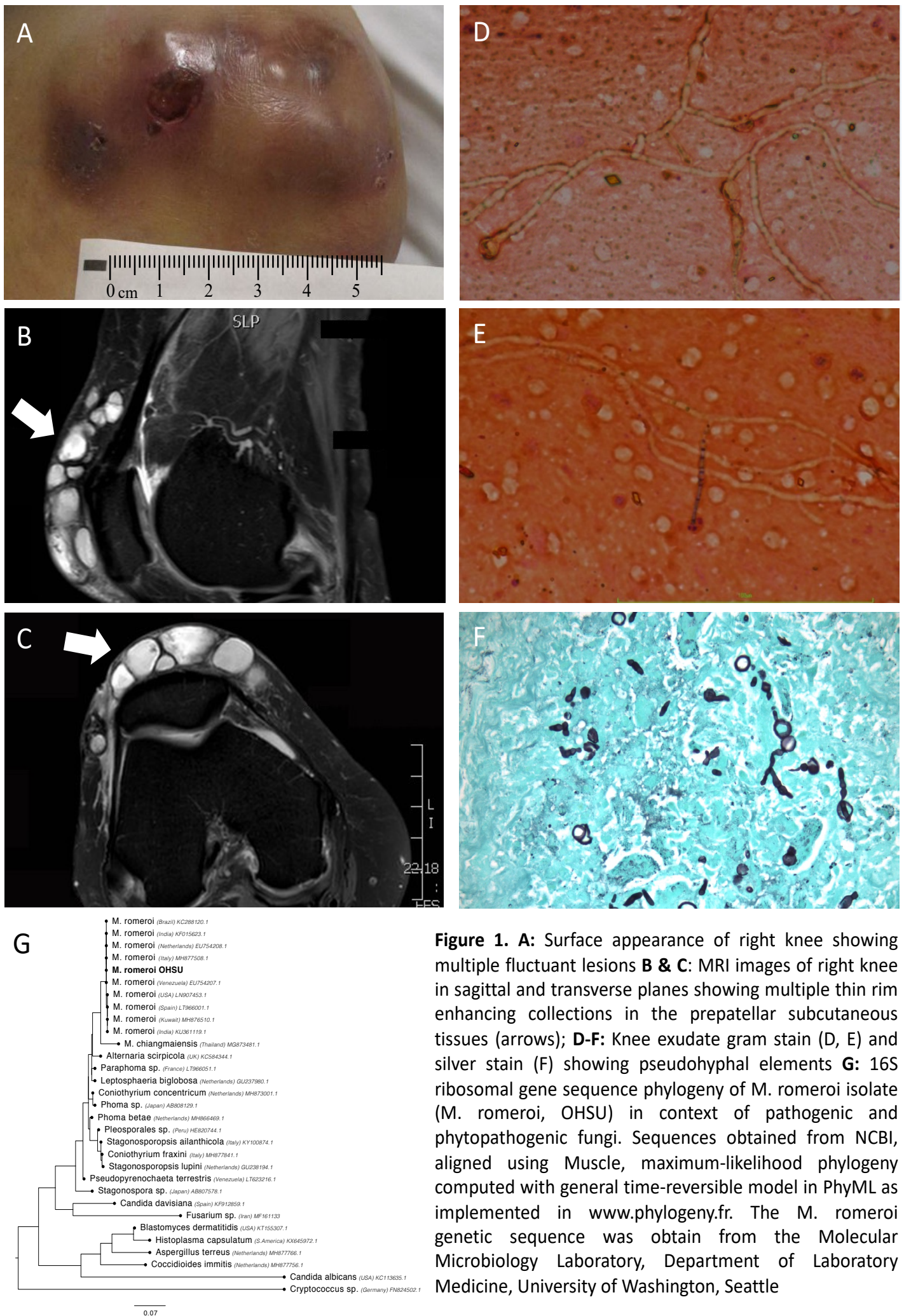


Figure 1. A: Surface appearance of right knee showing multiple fluctuant lesions B & C: MRI images of right knee in sagittal and transverse planes showing multiple thin rim enhancing collections in the prepatellar subcutaneous tissues (arrows); D-F: Knee exudate gram stain (D, E) and silver stain (F) showing pseudohyphal elements G: 16S ribosomal gene sequence phylogeny of *M. romeroi* isolate (*M. romeroi*, OHSU) in context of pathogenic and phytopathogenic fungi. Sequences obtained from NCBI, aligned using Muscle, maximum-likelihood phylogeny computed with general time-reversible model in PhyML as implemented in www.phylogeny.fr. The *M. romeroi* genetic sequence was obtained from the Molecular Microbiology Laboratory, Department of Laboratory Medicine, University of Washington, Seattle

Discussion

Melanised dematiaceous fungi are environmental saprophytes characterized by their ability to produce melanin creating a dark pigmented appearance in tissue [1,2]. There are over 150 species of medically relevant dematiaceous fungi distributed across at least nine phylogenetic orders and 70 genera. The isolate reported here is closely related to other *M. Romero* strains from various geographic regions worldwide (Figure 1 panel G). Darkly pigmented dematiaceous fungi can cause eumycetoma (slowly growing painless cutaneous masses characterized by tumefaction, the presence of mycolic granules and development of sinus tracts), chromoblastomycosis (slowly progressive hypertrophic verrucous plaques which may ulcerate or spread, and contain sclerotic “Medlar bodies”) and phaeohyphomycosis involving superficial infection of skin structures presenting as an encapsulated mass or nodule commonly seen on the extremities, deep organ infection such as pulmonary and central nervous system infections, or disseminated infection [1-3]. *Medicopsis romeroi* (previously *Pyrenochaeta romeroi*) typically causes phaeohyphomycosis in warmer climates, affecting immunocompromised individuals including those with acquired immunodeficiency syndrome, hematologic malignancies, diabetes mellitus, transplant recipients, and patients requiring prolonged steroid use [4-9]. *M. Romero* infrequently causes disease in normal hosts [10]. Infection occurs after minor traumatic skin inoculation precipitating dermatologic phaeohyphomycosis. In tissue, organisms appear as yeast-like cells or pseudo hyphal elements [11]. With darkly-pigmented conidia, spores and hyphae [1,5]. Grossly, colonies appear velvety, greyish, and green [12]. Microscopic identification of *M. Romero* is challenging, and molecular methods including ribosomal gene sequencing and matrix-assisted laser desorption ionization time-of-flight mass spectrometry are helpful in establishing the diagnosis [9,13,14]. Phaeohyphomycotic lesions are often cured by surgical excision alone, though antifungal therapy may be indicated in patients with extensive or refractory infections [5,6]. Limited antifungal susceptibility data suggest that *M. Romero* is relatively resistant to echinocandins, flu cytosine, fluconazole, but sensitive to Itraconazole, isavuconazole, and posaconazole [5,6,15]. Susceptibility data are inconsistent with respect to voriconazole and amphotericin [6,14,15]. Diabetes mellitus, corticosteroid use, and residence in Southeast Asia likely influenced her risk of acquiring both infections. The demographic history initially prompted concerns for other diagnoses including penicilliosis, sporotrichosis and histoplasmosis. *M. Romero* infection in this case likely originated from a remote asymptomatic inoculation followed by reactivation during immune suppression. Clinicians should remain vigilant for atypical infections in patients with a history of residence in areas endemic for unusual fungal pathogens, and should have a low threshold for utilizing sequence-based molecular tools to make a timely diagnosis. Treatment of

dematiaceous fungal infections remains challenging especially in those with invasive infections.

References

1. Revankar SG (2006) Phaeohyphomycosis. Infect Dis Clin North Am. 20: 609-620.
2. Revankar SG, Sutton DA (2010) Melanized fungi in human disease. Clin Microbiol Rev. 23: 884-928.
3. Revankar SG, Patterson JE, Sutton DA, Pullen R, Rinaldi MG (2002) Disseminated phaeohyphomycosis: review of an emerging mycosis. Clin Infect Dis. 34: 467-476.
4. Yadav S, Agarwal R, Singh S, Goel S (2015) *Pyrenochaeta romeroi* causing subcutaneous phaeohyphomycotic cyst in a diabetic female. Med Mycol Case Rep. 8: 47-49.
5. Khan Z, Ahmad S, Kapila K, Ramaswamy NV, Alath P, et al (2011) *Pyrenochaeta romeroi*: a causative agent of phaeohyphomycotic cyst. J Med Microbiol. 60: 842-846.
6. Abdolrasouli A, Gonzalo X, Jatan A, McArthur GJ, Francis N, et al (2016) Subcutaneous Phaeohyphomycosis Cyst Associated with *Medicopsis romeroi* in an Immunocompromised Host. Mycopathologia. 181: 717-721.
7. Brown GD, Meintjes G, Kolls JK, Gray C, Horsnell W, et al (2014) AIDS-related mycoses: the way forward. Trends Microbiol. 22: 107-109.
8. Kulkarni M, Jamale T, Hase N, Ubale M, Keskar V, et al (2017) Subcutaneous Phaeohyphomycosis Caused By *Pyrenochaeta Romeroi* in a Kidney Transplant Recipient: A Case Report. Exp Clin Transplant. 15: 226-227.
9. Chan YY, Tan AL, Tan BH (2014) subcutaneous abscess due to *Pyrenochaeta romeroi* in a renal transplant recipient. Singapore Med J. 55: e64-66.
10. Badali H, Chander J, Gulati N, Attri A, Chopra R, et al (2010) Subcutaneous phaeohyphomycotic cyst caused by *Pyrenochaeta romeroi*. Med Mycol. 48: 763-768.
11. McGinnis MR (1983) Chromoblastomycosis and phaeohyphomycosis: new concepts, diagnosis, and mycology. J Am Acad Dermatol. 8: 1-16.
12. Chowdhary A, Perfect J, de Hoog GS (2014) Black Molds and Melanized Yeasts Pathogenic to Humans. Cold Spring Harb Perspect Med. 5: a019570.
13. Fraser M, Borman AM, Johnson EM (2017) Rapid and Robust Identification of the Agents of Black-Grain Mycetoma by Matrix-Assisted Laser Desorption Ionization-Time of Flight Mass Spectrometry. J Clin Microbiol. 55: 2521-2528.
14. Singh A, Singh PK, Kumar A, Chander J, Khanna G, et al (2017) Molecular and Matrix-Assisted Laser Desorption Ionization-Time of Flight Mass Spectrometry-Based Characterization of Clinically Significant Melanized Fungi in India. J Clin Microbiol. 55: 1090-1103.
15. Ahmed SA, de Hoog GS, Stevens DA, Fahal AH, van de Sande WW (2015) In vitro antifungal susceptibility of coelomycete agents of black grain eumycetoma to eight antifungals. Med Mycol. 53: 295-301.