

# DISTICHIASIS

## What is distichiasis?

This is a condition that creates ocular discomfort due to the abnormal development of extra hairs along the eyelid margins. The hairs are different to normal eyelashes and can be directed towards the surface of the eye (cornea).

## What causes distichiasis?

Genetic factors are likely to be responsible, although the exact mode of inheritance is not clear. We normally advise against breeding from severely affected dogs.

## Are particular animals at risk?

We have seen distichiasis in many breeds and cross-bred dogs. In the UK the primary breeds affected include: Boxer, Bulldog, Flat-coated Retriever, Miniature Long-haired Dachshund, Miniature Poodle, Toy Poodle, Pekingese, Rough Collie, Shetland sheepdog, American Cocker Spaniel, English Cocker Spaniel and the Welsh Springer Spaniel.

## What are the signs of distichiasis?

This will depend on the severity of the disease, including the number of abnormal hairs in direct corneal contact. The continuing rubbing of the abnormal hairs onto the surface of the eye creates discomfort and can lead to corneal ulceration (see Corneal Ulceration Factsheets). An increased blink rate, excessive tear production and rubbing at the affected eye are common signs.

## Can both eyes be affected?

In the majority of cases both eyes are affected, but the severity of the disease may be different between eyes.

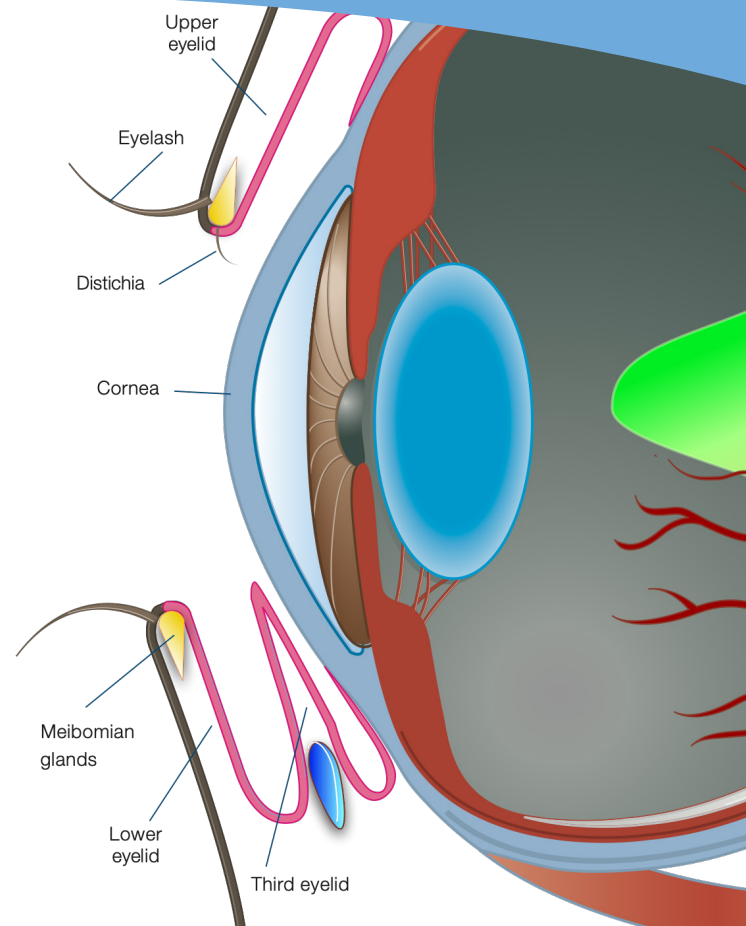
## Why don't you just pluck the hairs?

Although plucking may create instant relief, hair growth moves through a cycle and the root will produce a new hair within a short period. The new short hairs are stiff (stubble) and are more likely to create further corneal abrasion.

## What are the treatment options for distichiasis?

We usually recommend the precise freezing of the hair roots that produce the distichia. This will prevent the continued development of new hairs. The freezing process is carried out under general anaesthesia and each hair root will be treated at least three times in a freeze-thaw cycle. The freezing process will create some post-operative swelling and loss of pigmentation from the eyelid margins.

We prescribe a course of topical and oral medication to control the inflammation and the pigment slowly returns over a few months. Isolated larger hairs may be treated with electrolysis. This surgical procedure destroys the hair root with the precise delivery of an electrical current.



Occasionally we may recommend the surgical extraction of the hair roots under general anaesthesia. This is normally performed if a localised collection of abnormal hairs occur at a single location.

We will often observe incidental distichiasis in middle-aged and older dogs with no signs of ocular irritation or corneal damage. These cases may only need to be monitored periodically and we may prescribe topical lubricants if required.

## Can the distichia grow back after freeze therapy?

Only the roots of the visible hairs can be treated with freeze therapy and there may be other hairs along the eyelid margins that have not erupted at the time of surgery. The treated hair roots are unlikely to grow back, but the eruption of new hairs from untreated roots can occur particularly in young dogs or those more severely affected. Further treatment may be necessary if clinical signs of ocular discomfort reappear.